A first presentation of systemic autoinflammatory disease with DKA: a case report

SHARMAINE BRIGITTE LIM,[1] QIANXI WU,[1] JOHN ALEXANDER,[2] NATHAN CHEUK[3]

Br J Diabetes 2026;ONLINE AHEAD OF PUBLICATION
https://doi.org/10.15277/bjd.2026.514

Key words: case report, diabetic ketoacidosis, systemic autoinflammatory disease, colchicine, SGLT2 inhibitor

Abstract

Systemic autoinflammatory diseases (SAIDs) comprise a heterogeneous group of conditions driven by innate immune dysregulation, manifesting as sustained systemic inflammation and recurrent fevers. The diagnosis remains a clinical challenge due to the lack of pathognomonic features and limited access to definitive diagnostic tools. We report a complex case of an adult Caucasian male in regional Australia with type 2 diabetes (T2DM) treated with a sodium-glucose cotransporter-2 (SGLT2) inhibitor, who presented with lethargy, reduced oral intake and mild testicular discomfort and was diagnosed with diabetic ketoacidosis (DKA). Although his DKA resolved promptly with insulin and fluid therapy, he subsequently developed persistent daily spiking fevers and marked systemic inflammation without an identifiable infectious, autoimmune or malignant cause. Following a protracted hospitalisation, multiple unsuccessful antibiotic courses and extensive investigations, a diagnosis of systemic autoinflammatory disease was made. Colchicine treatment resulted in resolution of fever within 48 hours and progressive improvement in inflammatory markers. This case underscores the need for clinical suspicion of rarer conditions in patients presenting with relatively common metabolic disturbances.

Introduction

Systemic autoinflammatory diseases (SAIDs) are a group of heterogeneous conditions characterised by inappropriate and sustained systemic inflammation secondary to a dysregulated innate immune system, typically presenting with recurrent fever and other non-specific inflammatory symptoms.[1,2] The aetiology of SAIDs is considered to be overactivation of the innate immune system, resulting in excessive production of cytokines and other immune complexes.[1,3] The innate immune system, comprising cells such as monocytes, macrophages and neutrophils, provides the body's rapid, non-specific first line of immune defence, in contrast to the antigen-specific responses of the adaptive immune system.[1] Based on their aetiology, SAIDs are often subcategorised into monogenic (such as familial Mediterranean fever) or, more commonly, polygenic (or multifactorial), with no single gene identified.[1,4]

Diagnosis of SAIDs is often extremely challenging due to their non-specific clinical features and the lack of accessible definitive diagnostic tools. The average delay in diagnosis is up to 7.3 years, as a result of the extensive diagnostic workup (such as genetic testing) required before landing on the SAIDs diagnosis.[1]

When compared to SAIDs, diabetic ketoacidosis (DKA) is a common but life-threatening complication of diabetes which is encountered much more frequently in hospital practice. While classically associated with type 1 diabetes (T1DM), it is increasingly observed in type 2 diabetes mellitus (T2DM), particularly alongside the use of sodium-glucose cotransporter-2 (SGLT2) inhibitors and glucagon-like peptide (GLP-1) agonists.[5,6,7]

Interestingly, there is limited evidence regarding the association between SAIDs and DKA across the diabetic spectrum. This case study illustrated a rare case of a patient with the first presentation of SAIDs following an episode of diabetic ketoacidosis.

Patient information

A 68-year-old Caucasian man with T2DM diabetes (on empagliflozin), atrial fibrillation and hypertension presented to a regional hospital with a four-day history of severe lethargy, reduced oral intake, and one week of mild testicular discomfort. His regular medications included sotalol 40mg once daily, apixaban 5mg twice daily, rosuvastatin 10mg once daily, metformin/empagliflozin combination 1000mg/12.5mg 1 tablet twice daily, linagliptin 5mg once daily and gliclazide 30 mg once daily.

1. Bendigo Health, Bendigo, Victoria, Australia
2. Endocrinologist and General Medicine Physician, Bendigo Health, Bendigo, Victoria, Australia
3. Department of General Medicine, Bendigo Health, Bendigo, Victoria, Australia

Address for correspondence: Dr Sharmaine Brigitte Lim
Bendigo Health, 100 Barnard Street, Bendigo, Victoria, Australia, 3550
E-mail: limsharmaine@yahoo.com

Table 1. Baseline blood tests six months prior to admission

Test	Result	Reference range
Urea	6.6 mmol/L	3-10 mmol/L
Creatinine	72 umol/L	60-110 umol/L
Estimated glomerular filtration rate (eGFR)	>90 ml/min	>60 ml/min
HbA_{1c}	7.9% or 63mmol/mol	< 6% or < 42mmol/L

The patient had a documented six-year history of diabetes mellitus, complicated by diabetic retinopathy of unclear duration. No other microvascular or macrovascular complications had been identified. The patient had no history of DKA, hyperosmolar hyperglycaemic state or severe hypoglycaemia. He had normal renal function, with eGFR> 90ml/min and a HbA_{1c} of 7.9% prior to admission (Table 1).

The patient denied any gastrointestinal, respiratory, coryzal, dental, neurological or other urological symptoms. He denied any subjective fever, rash/skin changes or wound. The patient had a history of childhood bronchitis and one prior episode of pneumonia six years before. He had no history of urinary tract procedures, prosthetic joints or intravenous drug use. The patient was a retired mechanic with a history of asbestos exposure over 14 years, later working as a truck driver and in a rubber factory. He lived on a 40-acre rural property in Australia with his wife, drinking mostly tank water. His environmental exposures included close contact with pet birds, sheep and other native animals. He frequently worked in his vegetable garden using fresh potting mix, had a 0.14 pack-year history of smoking, and quit smoking 20 years before. He had no recent travel history. He was not currently sexually active. The patient had no personal history of autoimmune or autoinflammatory diseases and no known family history of such conditions. The patient was not of Mediterranean descent.

Clinical findings

On initial presentation, the patient looked fatigued. He was normotensive but in rapid atrial fibrillation (heart rate 90-120 bpm). He was afebrile, with a normal respiratory rate and oxygen saturation. Scrotal examination revealed mild bilateral testicular tenderness without signs of local infection. He had no rash anywhere on his body. His initial blood tests showed a bicarbonate of 12mmol/L, blood glucose of 16.6mmol/L and blood ketones of 4.5 mmol/L, which confirmed a diagnosis of DKA. An initial diagnosis of SGLT2i-induced DKA was made and he was started on DKA treatment as per the hospital protocol, with intravenous fluids, insulin and glucose infusions along with monitoring of electrolytes, glucose and ketones.

Though his DKA resolved promptly after insulin/glucose infusion, he developed persistent, daily spiking fevers up to 39°C from day 2 of admission, with a cyclical pattern (the fever spiked at early morning and late afternoon). He reported ongoing profound constitutional symptoms with malaise, yet no localising infectious symptoms developed throughout his hospital stay.

Table 2. Blood results on admission

Test	Result	Reference range
Venous blood pH	7.32	7.35 – 7.45
Venous bicarbonate	12 mmol/L	22 – 26mmol/L
Blood glucose	16.6 mmol/L	4 -7.8 mmol/L
Blood ketone	4.5 mmol/L	<0.6mmol/L
HbA_{1c}	7.5% or 58mmol/mol	<6% or <42mmol/L
C-reactive protein	260 mg/L	<3 mg/L
White cell count	19.7 x 10^9/L	4 – 11 x 10^9/L
Neutrophil count	16.5 x 10^9/L	2 – 8 x 10^9/L
Platelet count	558 x 10^9/L	150 – 450 x10^9/L

Diagnostic assessment

A comprehensive workup was initiated to investigate the patient's persistent fever and systemic inflammation. The clinical presentation, characterized by markedly elevated C-reactive protein (CRP), along with a high white cell count (WCC) with neutrophilia, strongly suggested a systemic inflammatory process (Table 2). Serum protein studies revealed hypoalbuminemia, hyperglobulinemia and elevated levels of IgG and IgA, consistent with an acute-phase inflammatory response. Complement levels (C3 and C4) were also elevated, further supporting the suspicion of systemic inflammation. He had multiple urine analyses with no growth but had episodes of microscopic haematuria with erythrocyte counts at 194 x 10 ^6 /L, along with numerous leucocytes. Multiple blood cultures were taken but all his blood cultures remained sterile throughout his hospital stay.

An extensive infectious disease workup yielded negative results for common infections, including tuberculosis, hepatitis, human immunodeficiency virus and various viral infections (e.g. Epstein-Barr virus, cytomegalovirus, rubella, varicella zoster and measles). Quantiferon testing for tuberculosis was indeterminate, but there was no clinical or radiological evidence of tuberculosis.

Immunological investigations, including tests for autoimmune diseases, were largely negative. These included negative results for autoimmune hepatitis, primary biliary cholangitis, coeliac disease and systemic lupus erythematosus (e.g. antinuclear antibody, anti-dsDNA, antineutrophil cytoplasmic antibody, anti-Sm). Additionally, the alpha-1-antitrypsin level was slightly elevated, indicating an acute-phase response.

Imaging studies, including PET-CT and CT chest, showed diffuse low-grade fluorodeoxyglucose uptake consistent with systemic inflammation, with no focal lesions or malignancy identified. Ultrasound of the testes showed bilateral hydrocoele with no ultrasound features of acute epididymo-orchitis. CT angiography and ultrasound studies of the renal tract and abdomen were unremarkable, ruling out major organ involvement or infection. A transthoracic echocardiogram showed mobile vegetation present on the left coronary cusp of

the aortic valve but trans-oesophageal echocardiogram showed no evidence of infective endocarditis.

Due to slightly increased uptake in the bone marrow on the PET-CT scan, a bone marrow biopsy was performed. Bone marrow aspiration and biopsy showed mild hypercellularity with reactive granulopoiesis and megakaryopoiesis, but no evidence of myeloproliferative or lymphoproliferative disorders. Testing for the JAK2 mutation was negative. Free light chain testing suggested reactive inflammation rather than monoclonal proliferation, as both kappa and lambda free light chains were elevated, but the kappa/lambda ratio remained normal.

Random skin biopsies revealed superficial perivascular dermatosis without specific signs of autoimmune diseases (for example, no granulomas or vasculitis).

Although the clinical presentation was not typical, T1DM autoantibodies were also sent to explore out a new diagnosis of TDM. The results were negative.

Differential diagnoses

The initial differential diagnoses considered for the patient included infection, autoimmune disorders and malignancy. Throughout his hospital stay, there was input from various specialists and an extensive series of tests and evaluations was conducted to exclude these possibilities.

Infectious causes were ruled out through negative results from blood cultures, viral polymerase chain reaction and serology. Malignancy was excluded after a bone marrow biopsy and PET scan showed no signs of cancer. Autoimmune conditions were also excluded based on negative results from a full autoimmune and vasculitis screen, along with a normal complement profile.

The diagnosis of systemic autoinflammatory disease (SAID) in this case was reached after systematically excluding other potential causes. Given the patient's clinical presentation, the multidisciplinary team (general medicine, endocrinology, infectious diseases, haematology, renal, respiratory and rheumatology teams) consensus was to initiate treatment for a SAID.

For at least 40–60% of patients with phenotypes typical of SAIDs, a distinct diagnosis remains elusive, leading to undefined SAIDs,[1] and while the precise diagnosis for this patient is still not known, familial Mediterranean fever (FMF) is one of the leading possibilities. FMF, caused by mutations in the MEFV gene on chromosome 16p, is classically characterized by recurrent episodes of fever and inflammation affecting the abdomen, chest or joints.[1] In this patient, scrotal pain was the presenting manifestation which, though not typical, has been reported as a possible but less common feature of FMF. This was highlighted by a series of case reports indicating that testicular pain could be an unexpected and the only presenting symptom of FMF.[7] This patient's clinical presentation aligns with two major criteria from the Tel Hashomer criteria for FMF, further supporting the likelihood of this diagnosis despite the atypical nature of the scrotal involvement.

Therapeutic intervention

The patient's DKA was treated according to the hospital's DKA protocol, with insulin infusion, fluid resuscitation and glucose. His SGLT2 inhibitor was stopped. His blood sugars normalised quickly, and he was commenced on twice-daily mixed insulin (insulin aspart/insulin aspart protamine). His blood glucose levels remained within an acceptable range throughout his hospital stay, although progressive uptitration of insulin was required.

Multiple broad-spectrum antibiotics were trialled during the patient's admission, as guided by the infectious disease department. The team concluded that an active infection was highly unlikely and recommended cessation of all antibiotics. All antibiotics were stopped from Day 10 of admission.

Given the need to avoid high-dose corticosteroids due to the patient's diabetes, a diagnostic-therapeutic trial of colchicine 500 mcg twice daily was initiated on day 25. The response was rapid and definitive. The patient's fevers resolved within 48 hours, his constitutional symptoms improved markedly, and inflammatory markers began a steady decline. Notably, this clinical improvement was not accompanied by any reduction in insulin requirements, as would have been expected with the resolution of any acute illness. Despite commencement of colchicine, his biphasic insulin dose required further uptitration from 0.47 units/kg/day to 0.60 units/kg/day to maintain glycaemic control. After discussion with the patient the decision was made to continue insulin long term for better control of his diabetes mellitus. He was discharged on day 34, with no fever recurrence and a close-to-normal CRP. Follow-up clinics in infectious disease and rheumatology were arranged, and he continued to take colchicine 500 micrograms twice daily.

Follow-up and outcomes

Following discharge, the patient was continued on colchicine. He was closely followed up at the infectious disease clinic locally and at rheumatology clinic at a tertiary centre. After two months of colchicine treatment it was successfully discontinued, as guided by the rheumatology team. Subsequent reviews over the following five months confirmed sustained clinical and biochemical remission, with no recurrence of fever, myalgia or testicular symptoms, and his CRP normalised to 2 mg/L. The patient regained his baseline weight, reporting only mild residual fatigue. Rheumatology discharged him with a plan for colchicine when required in case of a future flare, concluding a definitive monophasic episode of a systemic autoinflammatory disease. His T2DM remains well controlled with his discharge medications. His most recent HbA_{1c} was optimal at 6.2%. Diabetes-associated autoantibodies (GAD autoantibodies, IA-2 autoantibodies, ZnT8 autoantibodies) were tested and returned negative. At his final ID review, he remained clinically well and was discharged back to his general practitioner for long-term follow-up.

Discussion

This case highlights the rare and complex presentation of DKA in a patient with SAID. The patient's initial presentation with DKA secondary to SGLT2 inhibitor use and poor oral intake was complicated by persistent fever and systemic inflammation, despite appropriate antibiotic therapy. Investigations, including

Figure 1. Temperature trend and treatment timeline during the patient's hospital admissions. Individual temperature measurements are plotted against day of admission. Horizontal bars indicate the timing and duration of azithromycin, ceftriaxone, flucloxacillin, amoxicillin–clavulanic acid, vancomycin, doxycycline and colchicine therapy.

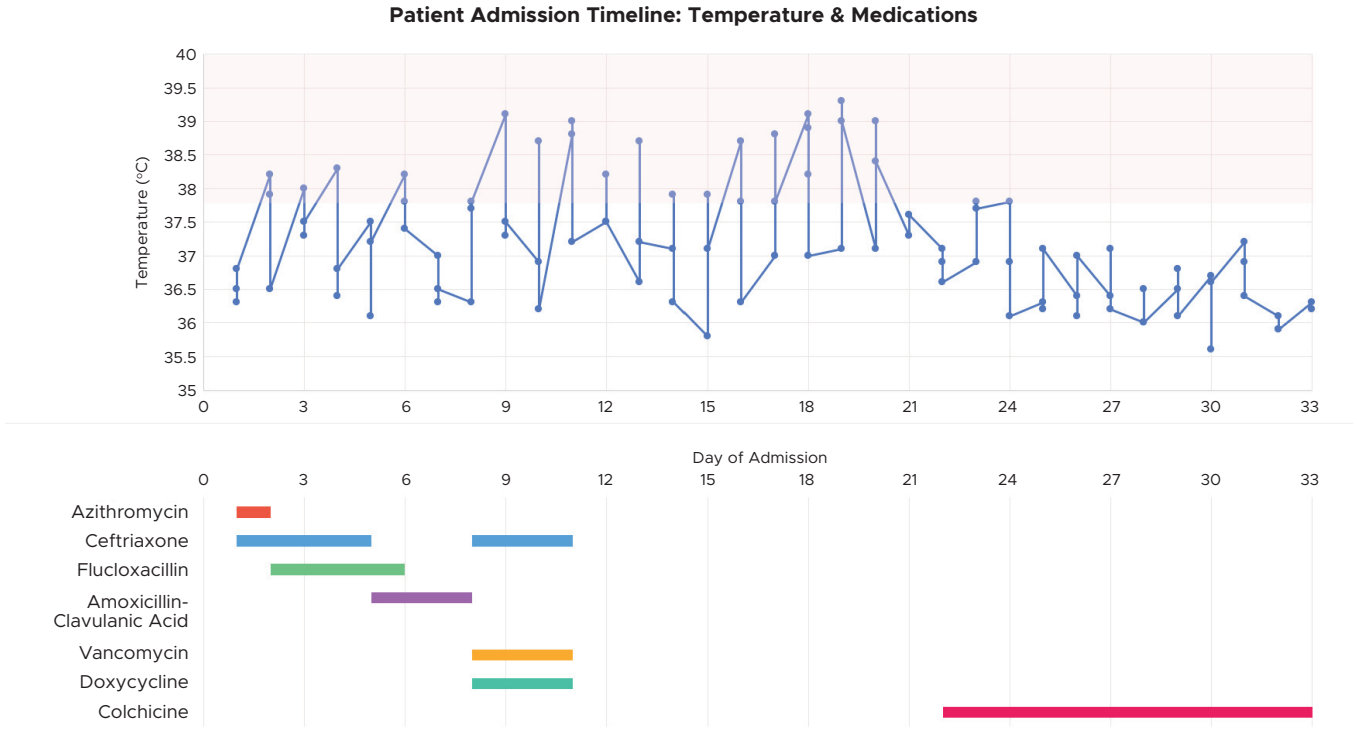

elevated inflammatory markers (CRP, WCC and neutrophils), hyperfibrinogenemia and abnormal serum protein studies, ultimately led to the diagnosis of an autoinflammatory disorder. Although there are multiple risk factors for his presentation with DKA, underlying SAID would have added to his acute presentation. The rapid resolution of fever following colchicine therapy, which is commonly used to treat familial Mediterranean fever (FMF) and other autoinflammatory conditions, further supported this diagnosis. This response serves as a key diagnostic clue, especially when genetic testing is not immediately available or if the patient lacks a definitive genetic diagnosis.

SAIDs are typically driven by dysregulated innate immunity, often involving mutations in inflammasomes, leading to excessive production of pro-inflammatory cytokines.[8] In this patient the combination of systemic inflammation and metabolic derangements may reflect a unique interplay between autoinflammation and DKA.

Over the past decades, the interplay between diabetes mellitus and pro-inflammatory cytokines has been well documented by multiple meta-analyses and systematic reviews. Chronic low-grade inflammation is known to promote insulin resistance through interference with insulin signalling pathways and to exert direct toxic effects on pancreatic β-cell function, ultimately contributing to the onset and progression of T2DM.[9,10] Furthermore, a clear association has been demonstrated between elevated CRP and increased T2DM risk.[9]

However, as a known complication of diabetes, the first presentation of DKA in the setting of systemic autoinflammatory disease is not well reported. It is not unreasonable to deduce that the cytokine storm in autoinflammatory conditions may have partially contributed to the DKA presentation, or vice versa, where severe metabolic stress exacerbated the inflammatory cascade. This case is notable for its diagnostic challenges, where the lack of an infectious aetiology and the patient's response to colchicine pointed toward an autoinflammatory origin of the systemic inflammation, distinguishing it from the more common inflammation-driven metabolic syndrome.

The prompt resolution of fever following colchicine initiation reinforces the role of colchicine in managing systemic inflammation in diseases such as FMF. Colchicine is a widely used anti-inflammatory agent that exerts its effects through inhibition of inflammatory cell activation and recruitment, as well as disruption of inflammasome activity, which plays a central role in the inflammatory response.[11]

This case highlights the importance of considering systemic autoinflammatory diseases in the differential diagnosis of DKA with unexplained fever, and the potential for colchicine to manage such conditions effectively. Importantly, in patients treated with SGLT2 inhibitors who present with DKA, the SGLT2 inhibitor should not necessarily be assumed to be the sole precipitating factor. Careful evaluation of the clinical features and consideration of other contributing or concurrent conditions

Key messages

- Consider systemic autoinflammatory diseases (SAIDs) for unexplained fevers accompanied by common metabolic disturbances.
- Maintain a high index of suspicion for SAIDs if symptoms fail to improve with antimicrobials.
- A rapid response to colchicine strongly supports an underlying autoinflammatory aetiology.

remain essential to identifying the underlying cause and providing appropriate management. Further research is needed to understand the pathophysiological mechanisms linking autoinflammatory diseases to metabolic disturbances such as DKA.

Patient perspective

The patient felt that the illness and prolonged hospital admission had taken a significant toll on him. He spent much of his admission in bed with limited activity and found the length of his hospital stay difficult. Although he has improved, he feels that he has not yet regained his previous energy levels and continues to have difficulty with daily activities and walking longer distances. Despite these ongoing limitations, he remains grateful for the care he received during his admission.

© 2026. This work is openly licensed via CC BY ND 4.0.
This license enables reusers to copy and distribute the material in any medium or format in unadapted form only, and only so long as attribution is given to the creator. The license allows for commercial use.
CC BY ND includes the following elements: BY – credit must be given to the creator. ND – No derivatives or adaptations of the work are permitted.

Conflict of interest None to declare.
Funding None.

Patient consent Written informed consent was obtained from the patient for the publication of this case report and any accompanying images or clinical information.

References

1. Krainer J, Siebenhandl S, Weinhäusel A. Systemic autoinflammatory diseases. *J Autoimmun* 2020;**109**:102421. https://doi.org/10.1016/j.jaut.2020.102421.
2. Children's Hospital Boston. Systemic autoinflammatory diseases (SAIDs) [Internet]. Boston (MA): Children's Hospital Boston; 2026 [cited 2026 Jan 26]. Available from: https://www.childrenshospital.org/conditions-treatments/systemic-autoinflammatory-diseases-saids.
3. Hoffman HM, Broderick L. The role of the inflammasome in patients with autoinflammatory diseases. *J Allergy Clin Immunol* 2016; **138**(1):3–14. https://doi.org/10.1016/j.jaci.2016.05.001.
4. Hua Y, Wu D, Shen M, Yu K, Zhang W, Zeng X. Phenotypes and genotypes of Chinese adult patients with systemic auto-inflammatory diseases. *Semin Arthritis Rheum* 2019;**49**(3):446–52. https://doi.org/10.1016/j.semarthrit.2019.05.002.
5. Taylor SI, Blau JE, Rother KI. SGLT2 inhibitors may predispose to ketoacidosis. *J Clin Endocrinol Metab* 2015;**100**(8):2849–52. https://doi.org/10.1210/jc.2015-1884. PMID: 26086329; PMCID: PMC4525004.
6. Thaibah HA, Banji OJF, Banji D, Alshammari TM. Diabetic ketoacidosis and the use of new hypoglycemic groups: real-world evidence utilizing the Food and Drug Administration Adverse Event Reporting System. *Pharmaceuticals (Basel)* 2025;**18**(2):214. https://doi.org/10.3390/ph18020214. PMID: 40006028; PMCID: PMC11858861.
7. Bahaa A, Nour A, Hamza A, *et al*. Scrotal pain in familial Mediterranean fever: a series of three case reports and literature review. *Mediterr J Rheumatol* 2025;**36**(3):497–501. https://doi.org/10.31138/mjr.180425.tar. PMID: 41122187; PMCID: PMC12536748.
8. An J, Marwaha A, Laxer RM. Autoinflammatory diseases: A review. *J Rheumatol* 2024;**51**(9):848-861. https://doi.org/10.3899/jrheum.2023-1209
9. Liu C, Feng X, Li Q, Wang Y, Li Q, Li Q. Adiponectin, TNF-α and inflammatory cytokines and risk of type 2 diabetes: A systematic review and meta-analysis. *Cytokine* 2016;**86**:100-109. https://doi.org/10.1016/j.cyto.2016.06.001.
10. Cao C, Yuan J, Gilbert ER, *et al*. Increased circulating interleukin concentrations in type 2 diabetes: a systematic review and meta-analysis. *Obes Rev* 2025;**26**:e13791. https://doi.org/10.1111/obr.13971
11. Leung YY, Yao Hui LL, Kraus VB. Colchicine--Update on mechanisms of action and therapeutic uses. *Semin Arthritis Rheum* 2015;**45**(3):341-50. https://doi.org/10.1016/j.semarthrit.2015.06.013. Epub 2015 Jun 26. PMID: 26228647; PMCID: PMC4656054.