# Atypical diabetic foot infection caused by *Salmonella enterica* serovar Enteritidis: a case report

BLETA FAZLIU,[1] SHEENA THAYYIL,[1] DEBORAH MODHA,[1] MARIE-FRANCE KONG,[1] EHTASHAM AHMAD[1,2]

*Br J Diabetes* 2026;ONLINE AHEAD OF PUBLICATION
https://doi.org/10.15277/bjd.2026.515

**Key words:** diabetic foot ulcer, diabetic foot infection, *Salmonella* Enteritidis, atypical wound infection, peripheral arterial disease, critical limb ischaemia, chronic kidney disease

## Abstract

Diabetic foot infections are a common complication in people with diabetes and are frequently caused by bacteria such as *Staphylococcus aureus* and beta-haemolytic *Streptococci*. We describe a case of an infection caused by *Salmonella enterica* serovar Enteritidis in a 62-year-old man with poorly controlled type 2 diabetes mellitus (T2DM), peripheral arterial disease (PAD) and chronic kidney disease (CKD) who presented with a foot ulcer.

The patient presented with a left second toe ulcer several months after a documented episode of gastrointestinal infection caused by *S*. Enteritidis. The same organism was identified from a wound culture of the foot ulcer. This was shown on whole genome sequencing to be identical to the original isolate, both having an identical Single Nucleotide Polymorphism (SNP) address. Despite targeted antimicrobial therapy and vascular intervention, the infection progressed, ultimately requiring partial toe amputation. Following multidisciplinary management, the surgical site healed satisfactorily.

This case emphasises the importance of early recognition of the causative organism in non-resolving diabetic foot infections, particularly in patients with multiple co-morbidities and impaired limb perfusion.

1. Diabetes Department, University Hospitals of Leicester NHS Trust, Leicester, UK
2. Leicester Diabetes Centre, University of Leicester, Leicester, UK

**Address for correspondence:** Dr Ehtasham Ahmad
Leicester Diabetes Department, Gwendolen Road, Leicester General Hospital, Leicester, LE5 4PW, UK
E-mail: ehtasham.ahmad3@nhs.net

## Introduction

Diabetic foot ulcers (DFU) are a common and serious complication of diabetes and a major cause of lower-limb morbidity worldwide.[1] Patients with a history of DFU have approximately twice the risk of death at 10 years compared with those with diabetes who do not have ulceration.[1] Infection is a frequent complication of DFU and a key driver of hospitalisation, limb loss and adverse clinical outcomes.[1] The microbiology of diabetic foot infections (DFI) is diverse and often polymicrobial, involving both Gram-positive organisms, particularly *Staphylococcus aureus*, beta-haemolytic *Streptococci* and Gram-negative organisms such as *Enterobacterales* group.[2] Isolation of Salmonella species in this setting is rare.

Non-typhoidal *Salmonella* species are predominantly associated with gastrointestinal infection but may also cause invasive extraintestinal disease, including involvement of soft tissue and bone, particularly in immunocompromised hosts.[3] In people with diabetes, underlying vascular insufficiency and immune dysfunction may further predispose to infection, while also complicating both diagnosis and management.[4] Consequently, as the prevalence of diabetes and its associated complications continues to rise, recognition of unusual pathogens in non-resolving DFI has become increasingly important to ensure accurate diagnosis and appropriate antimicrobial therapy.[2,5]

We report a case of a diabetic foot infection caused by *Salmonella enterica* serovar Enteritidis in a 62-year-old man with poorly controlled type 2 diabetes mellitus (T2DM), peripheral arterial disease (PAD) and chronic kidney disease (CKD). The infection occurred several months after hospitalisation for gastrointestinal infection caused by S. Enteritidis, raising consideration of delayed extraintestinal infection in a susceptible host. This case highlights the diagnostic challenges posed by rare pathogens in DFI and underscores the importance of early microbiological assessment and coordinated multidisciplinary management.

## Patient information

A 62-year-old man with poorly controlled T2DM presented to his General Practitioner (GP) in March 2025 with a left second toe ulcer, alongside a five-month history of worsening exertional leg pain.He denied any systemic symptoms suggestive of

sepsis. The ulcer was swabbed, and he was commenced on flucloxacillin 1000 mg four times a day before referral to the secondary care multidisciplinary diabetic foot clinic.

His medical history included a 16-year history of sub-optimally controlled diabetes, complicated by peripheral neuropathy, diabetic retinopathy and stage 3 CKD (eGFR 53ml/min/1.73m$^2$). He also experienced chronic distal foot pain, attributed to peripheral neuropathy, and had a significant cardiovascular history including two separate myocardial infarctions treated with coronary stenting and complicated by decompensated heart failure.

In the month preceding ulcer development, he had been referred by his GP to the vascular team for suspected intermittent claudication. Glycaemic control had been markedly poor for several years, with an $HbA_{1c}$ of 10.4% (90 mmol/mol) measured in May 2025 and values consistently exceeding 10% for at least four years prior to presentation. He was an ex-smoker and had no prior history of diabetic foot ulceration.

Eight months prior to ulcer development, he had been admitted with a severe gastrointestinal infection, confirmed on stool culture to be caused by the same species *S*. Enteritidis. This was further complicated by stage 2 acute kidney injury (AKI). Blood cultures were negative, and CT imaging of the abdomen and pelvis showed no evidence of colitis. He was treated with intravenous fluids, co-amoxiclav and ceftriaxone as per microbiology advice, which resulted in resolution of AKI, normalisation of inflammatory markers and gradual improvement in symptoms.

## Clinical findings

At initial presentation to the GP practice, a 1cm ulcer was noted on the medial aspect of the left second toe, with associated slough and surrounding erythema but no discharge or necrosis.

One week later, on first review with the multidisciplinary team (MDT) foot clinic on 14 March 2025, the ulcer had progressed to a necrotic lesion that probed to bone and was associated with a 6°C temperature difference compared with the contralateral foot (Figure 1). Handheld Doppler assessment in the clinic demonstrated biphasic signals in the left foot. He was reviewed a few weeks later, at which point he had worsening pain and second toe necrosis (Figure 2).

**Figure 1.** Ulcer at first presentation to diabetes foot clinic



**Figure 2.** Gangrene of the left second toe (3 weeks after initial presentation to foot clinic)



## Diagnostic assessment

Wound cultures obtained on 12 March 2025 grew *S*. Enteritidis, sensitive to amoxicillin ciprofloxacin and ceftriaxone, and *enterococcus* species, sensitive to amoxicillin and vancomycin. The *S*. Enteritidis was shown on whole genome sequencing to be identical to the original isolate, both having an identical Single Nucleotide Polymorphism (SNP) address. Plain radiography of the left foot at that time demonstrated radiographic features consistent with osteomyelitis, with associated soft-tissue gas within the second toe (Figures 3 and 4).

**Figure 3.** Gas within soft tissue overlying the left second distal phalanx

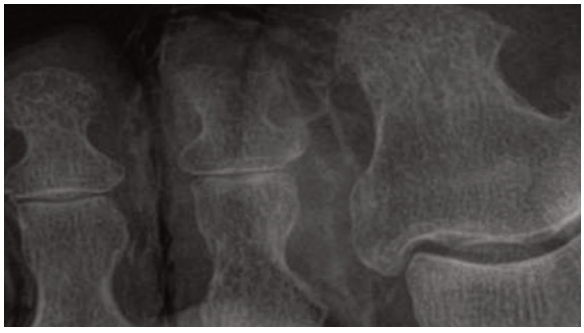

**Figure 4.** X ray of the left foot, showing osteomyelitis of the left distal second toe

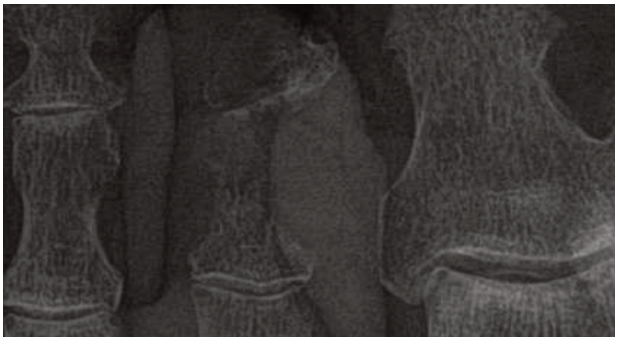

Duplex ultrasound performed in vascular clinic on 26 March 2025 demonstrated superficial femoral artery stenosis, with poor visualisation of the tibial vessels. At a vascular clinic review on 2 April 2025, clinical examination documented dry necrosis of the left second toe. Femoral and popliteal pulses were palpable, although weaker than expected, and no pedal pulses could be felt in the left foot. These findings were consistent with chronic limb-threatening ischaemic in the context of peripheral arterial disease and tissue loss. A plan was made for formal angiography and possible angioplasty.

Subsequent left lower limb angiography on 22 April 2025, performed in conjunction with angioplasty, demonstrated moderate calcified stenosis of the superficial femoral artery (SFA), mild popliteal artery (PA) stenosis and mild proximal anterior tibial artery (ATA) stenosis with occlusion of the mid-segment, with appearances suspicious for an acute thrombotic event. The distal anterior tibial (ATA) and dorsalis pedis arteries (DPA) were patent. The tibioperoneal trunk (TPT) was widely patent, with a mildly stenosed mid-peroneal artery. The posterior tibial artery (PTA) was occluded in its mid-segment, reconstituting above the ankle with patent flow into the foot.

Following presentation to the vascular emergency clinic, the patient was admitted to hospital from 7 to 9 May 2025 for ongoing rest pain and gangrene of the left second toe, despite the angioplasty in April 2025. Laboratory investigations demonstrated a raised white cell count (11.7 x $10^9$/L) with neutrophilia (9.76x$10^9$/L) and an elevated C-reactive protein (CRP) of 46mg/L. Glycaemic control remained poor, with an $HbA_{1c}$ of 10.4% (90 mmol/mol) at the time of admission. Repeat angiography and angioplasty were undertaken during this admission.

Due to ongoing foot pain, the patient was re-admitted to the hospital a few days later, on 20 May 2025. CRP was further elevated at 114mg/L although the white cell count and neutrophil levels had normalised. It was during this admission that the decision was made to proceed with the partial amputation of the left second toe.

## Therapeutic interventions

At initial assessment in the GP practice, the patient was commenced on oral flucloxacillin 500mg four times daily, which was increased to 1g four times a day after the development of discharge from the ulcer. On subsequent review in the MDT foot clinic, the ulcer had progressed to necrosis and probed to bone, raising concern for underlying osteomyelitis. Oral antimicrobial therapy was therefore escalated, with the addition of ciprofloxacin 500mg twice daily and metronidazole 400mg three times daily alongside flucloxacillin as per treatment for a moderate infection (IWGDF/IDSA classification).[6]

Following identification of S. Enteritidis and *Enterococcus* species from two consecutive deep wound swabs from the ulcer site two days apart, antimicrobial therapy was rationalised in accordance with sensitivities and microbiology advice. Treatment was adjusted to a targeted regimen with oral amoxicillin 1g three times a day in combination with ciprofloxacin 750mg twice daily. Amoxicillin was continued for a total duration of six weeks.

Given concerns regarding limb perfusion, with duplex ultrasound confirming superficial femoral artery stenosis and clinical progression to absent pedal pulses and dry toe necrosis, vascular intervention was undertaken. On 22 April 2025, an elective balloon angioplasty of the SFA and PA stenosis was performed. Subintimal angioplasty of the PTA and angioplasty of the PA stenosis were also undertaken, with good angiographic results and improved distal perfusion. The ATA occlusion was crossed but not treated with angioplasty due to appearances consistent with a soft thrombus. This intervention resulted in improved distal perfusion and initial improvement in second toe pain.

Despite this intervention, the patient was admitted to hospital from 7 to 9 May 2025 following a review in the vascular emergency clinic for ongoing rest pain. It was considered to be predominantly ischaemic, with superimposed infection and progression of digital gangrene. Repeat duplex ultrasound performed on 7 May 2025 demonstrated stenosis at the origin of the ATA and re-occlusion of the PTA. In view of these findings, repeat endovascular intervention was undertaken on 9 May 2025, including angioplasty of the left SFA and recanalisation of the ATA. Angioplasty of the PTA was attempted but was unsuccessful due to immediate recoil, and overall clinical benefit was deemed to be limited as it was most likely a soft thrombus. The DFI was treated with intravenous piperacillin-tazobactam and teicoplanin for three days as per IWGDF/IDSA classification of severe infection, with subsequent step-down to oral flucloxacillin to complete a three-week course on discharge.

Ongoing infection and tissue necrosis ultimately necessitated surgical intervention, and the patient was re-admitted to hospital a few days later. He underwent a partial amputation of the left second toe on 22 May 2025 without any peri-operative complications.

## Follow-up and outcomes

Following surgical intervention, the left second toe amputation was fully healed at review in the diabetes foot clinic on 27 June 2025 (Figure 5). The patient was subsequently discharged from

**Figure 5.** Distal amputation of the left second toe, with complete healing of the wound site



specialist foot clinic follow-up, with referral to community podiatry and ongoing vascular follow-up.

## Timeline

To aid interpretation of the sequence of events and the relationship between vascular, microbiological and surgical interventions, a summary timeline of key clinical milestones is provided in Table 1.

**Table 1.** Timeline of clinical events

| Date | Event |
|---|---|
| July 2024 | Hospitalised with severe gastroenteritis after travel to Cape Verde. Stool culture positive for *Salmonella enterica* serovar Enteritidis. Treated with IV antibiotics; admission complicated by AKI, which resolved. |
| February 2025 | GP review for worsening exertional leg pain; referred to vascular services. |
| 07 March 2025 | First presentation to GP with left second toe ulcer. No signs of necrosis. Commenced on flucloxacillin and referred to MDT foot clinic. |
| 12 March 2025 | Ulcer re-examined in primary care; wound swab obtained due to clinical progression. |
| 14 March 2025 | First MDT foot clinic review: necrotic ulcer probing to bone (Figure 1). Treated for suspected osteomyelitis. Antibiotic therapy intensified |
| 20 March 2025 | Wound culture grew *Salmonella* as above. Antibiotics rationalised following microbiology advice. |
| 26 March – 02 April 2025 | Vascular review identified SFA stenosis with poor visualisation of tibial vessels. Plan for angiography and angioplasty. |
| 22 April 2025 | Elective left lower limb angioplasty for ongoing pain and digital gangrene. |
| 07–09 May 2025 | GP referral to vascular emergency clinic. Patient admitted with ongoing severe rest pain and worsening gangrene. Repeat angioplasty due to ATA origin stenosis and re-occlusion of the PTA. Treated with IV antibiotics and discharged with a course of oral flucloxacillin. |
| 20–24 May 2025 | Re-admitted with left second toe infection. Underwent partial left second toe amputation on 22 May 2025. |
| 27 June 2025 | Surgical site fully healed. |

## Discussion

Diabetic foot infections are typically caused by Gram-positive cocci such as *Staphylococcus aureus* and beta-haemolytic *Streptococci*.[2] In addition, Gram-negative bacilli, including members of the *Enterobacterales* group and *Pseudomonas aeruginosa* and anaerobic bacteria, may also contribute, depending on the severity of the infection. Isolation of *S*. Enteritidis in this context is therefore unusual. The delayed presentation following an apparently resolved episode of gastrointestinal infection raises important questions regarding bacterial persistence and host susceptibility. Non-typhoidal *Salmonella* species, including *S*. Enteritidis, are known to establish persistent infection or long-term carriage in humans, through intracellular survival within host cells, particularly macrophages, thereby evading immune clearance and antimicrobial therapy and permitting recrudescence months after an initial gastrointestinal infection.[7] This provides a biologically plausible mechanism for delayed extraintestinal infection in susceptible hosts, particularly those who are immunocompromised. While it is not possible to distinguish persistent infection from re-infection definitively, in this case the absence of recurrent gastrointestinal symptoms and the temporal relationship to the initial enteric infection support a plausible link to the earlier episode of *Salmonella* gastroenteritis.

Several host-related factors in this patient created a permissive environment for the development and persistence of infection. Long-standing, poorly controlled diabetes is associated with impaired innate immune function, particularly affecting neutrophil chemotaxis, phagocytosis and oxidative killing, thereby reducing the ability to clear bacterial pathogens from infected tissue.[8] This immune dysfunction was further compounded by significant PAD, with impaired distal perfusion limiting effective immune cell trafficking and antimicrobial delivery to the affected tissues, contributing to delayed wound healing and impaired infection control.[9] Reduced antibiotic penetration into ischaemic tissue may also have contributed to inadequate local antimicrobial exposure, despite susceptibility demonstrated on culture. Moreover, co-existing stage 3 CKD may have further increased susceptibility through uraemic toxin-mediated impairment of both innate and adaptive immune responses, while also influencing antimicrobial pharmacokinetics and dosing requirements.[10] On clinical grounds, we judged the 2nd toe ulcer to have mixed ischaemic and neuropathic features, with superimposed local infection and osteomyelitis. Longstanding peripheral neuropathy may also have made it more difficult to distinguish neuropathic pain from vascular pain during this episode.

This case highlights several important considerations in the management of complex diabetic foot infections. Accurate microbiological diagnosis is essential, particularly when infection fails to respond to standard empirical therapy. In this context, deep tissue cultures after adequate debridement are recommended to identify causative organisms and guide targeted antimicrobial therapy[11] Although in this case plain radiography demonstrated features consistent with osteomyelitis; management decisions were guided by clinical progression, with worsening infection, impaired limb perfusion and severe pain ultimately necessitating surgical intervention.

This case underscores the importance of a coordinated multidisciplinary approach integrating diabetology, microbiology, vascular surgery and specialist podiatry.[12,13] Such collaboration is crucial for optimising antimicrobial management, assessing and addressing limb perfusion, achieving glycaemic stabilisation and guiding timely surgical intervention. Early microbiological identification, including recognition of less common pathogens in DFIs, may facilitate more appropriate antimicrobial therapy and help reduce the risk of prolonged infection, repeat hospitalisation and limb loss.[13]

## Conclusion

This case highlights the need to consider rare or unusual

### Key messages

- Unusual pathogens should be considered in diabetic foot infections, particularly in patients with multiple host vulnerabilities and immune dysfunction
- Early microbiological sampling is essential when diabetic foot infections fail to respond to empirical antibiotics.
- Multidisciplinary management, integrating podiatry, microbiology, vascular surgery and diabetes team is crucial for infection resolution and limb preservation in severe cases.

pathogens in the aetiology of diabetic foot infections, particularly in patients with multiple predisposing host factors and a history of prior systemic infection. Delayed extraintestinal infection may occur months after an initial episode of gastrointestinal infection, especially in the context of poorly controlled diabetes, PAD and CKD. In such cases, failure to respond to standard empirical therapy should prompt early microbiological sampling to facilitate identification of pathogens and guide targeted antimicrobial treatment. Optimal management in this case required a coordinated multidisciplinary approach integrating microbiological diagnosis, vascular assessment, glycaemic management and timely surgical intervention, which was central to achieving infection resolution and avoiding more extensive limb loss. Continued vigilance for delayed or recrudescent infection, together with careful consideration of patient-specific host vulnerabilities, are essential in the management of complex diabetic foot disease.

© 2026. This work is openly licensed via CC BY ND 4.0.
*This license enables reusers to copy and distribute the material in any medium or format in unadapted form only, and only so long as attribution is given to the creator. The license allows for commercial use.*
*CC BY ND includes the following elements: BY – credit must be given to the creator. ND – No derivatives or adaptations of the work are permitted.*

**Conflict of interest** None to declare.
**Funding** None.

**Patient consent** Written informed consent was obtained from the patient for the publication of this case report and any accompanying images or clinical information.

**References**

1. Armstrong DG, Boulton AJM, Bus SA. Diabetic foot ulcers and their recurrence. *N Engl J Med* 2017;**376**(24):2367–75. https://doi.org/10.1056/NEJMra1615439
2. Rajab AAH, Hegazy WAH. What's old is new again: Insights into diabetic foot microbiome. *World J Diabetes* 2023;**14**(6):680–704. https://doi.org/10.4239/wjd.v14.i6.680
3. Hohmann EL. Nontyphoidal salmonellosis. *Clin Infect Dis* 2001; **32**(2):263–269. https://doi.org/10.1086/318457
4. Holt RIG, Cockram CS, Ma RCW, Luk AOY. Diabetes and infection: review of the epidemiology, mechanisms and principles of treatment. *Diabetologia* 2024;**67**(7):1168–80. https://doi.org/10.1007/s00125-024-06102-x
5. Duncan BB, Magliano DJ, Boyko EJ. IDF Diabetes Atlas 11th edition 2025: global prevalence and projections for 2050. *Nephrol Dial Transplant* 2026;**41**(1):7–9. https://doi.org/10.1093/ndt/gfaf177
6. Senneville É, Albalawi Z, van Asten SA, *et al.* IWGDF/IDSA guidelines on the diagnosis and treatment of diabetes-related foot infections (IWGDF/IDSA 2023). *Diabetes Metab Res Rev* 2024;**40**(3):e3687. https://doi.org/10.1002/dmrr.3687. Epub 2023 Oct 1. PMID: 37779323.
7. Gal-Mor O. Persistent infection and long-term carriage of typhoidal and nontyphoidal salmonellae. *Clin Microbiol Rev* 2019;**32**(1): e00088-18. https://doi.org/10.1128/CMR.00088-18
8. Dowey R. A bittersweet response to infection in diabetes. *Clin Exp Immunol* 2021;**204**(1):1–15. https://doi:10.1111/cei.13685
9. Kim J. The pathophysiology of diabetic foot: a narrative review. *J Yeungnam Med Sci* 2023;**40**(4):328–34. https://doi.org/10.12701/jyms.2023.00731
10. Espi M, Koppe L, Fouque D, Thaunat O. Chronic kidney disease-associated immune dysfunctions: impact of protein-bound uremic retention solutes on immune cells. *Toxins (Basel)* 2020;**12**(5):300. https://doi.org/10.3390/toxins12050300
11. Lipsky BA, Berendt AR, Cornia PB, *et al*; Infectious Diseases Society of America. 2012 Infectious Diseases Society of America clinical practice guideline for the diagnosis and treatment of diabetic foot infections. *Clin Infect Dis* 2012;**54**(12):e132–e173. https://doi.org/10.1093/cid/cis346.
12. Musuuza J, Sutherland BL, Kurter S, Balasubramanian P, Bartels CM, Brennan MB. A systematic review of multidisciplinary teams to reduce major amputations for patients with diabetic foot ulcers. *J Vasc Surg* 2020;**71**(4):1433–46.e3. https://doi.org/10.1016/j.jvs.2019.08.244.
13. National Institute for Health and Care Excellence (NICE). Diabetic foot problems: prevention and management. NICE guideline [NG19]. London: NICE; 2015. Available from: https://www.nice.org.uk/guidance/ng19/resources/diabetic-foot-problems-prevention-and-management-pdf-1837279828933