

Null variant homozygous familial hypercholesterolaemia: genetic analysis and 34 years follow-up

CHARLES VAN HEYNINGEN

Br J Diabetes 2024;**24**(2):155-157
<https://doi.org/10.15277/bjd.2024.459>

Key words: homozygous familial hypercholesterolaemia, LDL receptor activity, liver transplantation

Abstract

A seven-year-old girl presented with lack of energy, a systolic heart murmur, total cholesterol of 18.7 mmol/L and skin xanthomas. During aortic valve surgery, atheroma was found in the ascending aorta. Initial treatments were diet, lipid-regulating medication and lipoprotein apheresis followed by aortic valve replacement and coronary artery bypass grafting.

At age 17 years she had a combined heart and liver transplant. Thirteen years later she developed a recurrence of ischaemic heart disease symptoms and autoimmune chronic liver disease and hence was given a second liver transplant. She died from a cardiac arrest at the age of 41 years caused by cardiac allograft immune vasculopathy.

Genome analysis showed two mutations in the LDL receptor gene, confirming a diagnosis of homozygous familial hypercholesterolaemia. Complete loss of LDL receptor function was demonstrated on fibroblast bioassay. New LDL receptor-independent therapies for homozygous familial hypercholesterolaemia have recently become available.

Introduction

Homozygous familial hypercholesterolaemia (HoFH) has a global prevalence of about one per 300,000. It causes severe premature cardiovascular atherosclerosis affecting major arteries and may present in childhood with coronary events. We describe a child who presented at seven years of age, was treated surgically with a heart and two liver transplants and was followed up to the age of 41 years.

Retired, Cambridge, UK

Address for correspondence: Dr Charles Van Heyningen
14 Harvest Road, Cambridge, CB2 9PH, UK
Email: charlesvh@icloud.com

Case report

A 7-year-old girl complained of lack of energy. A mid-systolic heart murmur suggesting aortic stenosis and cutaneous xanthomas on her knees and buttocks were found. Her mother's serum total cholesterol was 9.6 mmol/L and her father's 8.6 mmol/L. Her total cholesterol was 18.7 mmol/L and serum apolipoprotein B was three times the upper reference range at 3.56 g/L (0.75-1.25 g/L). An aortic valvotomy was performed and extensive atheroma was found in the ascending aorta. Initial treatment was with diet and probucol which reduced serum total cholesterol to 14.8 mmol/L. From the age of 10 years, she was treated with bi-weekly lipoprotein apheresis which reduced total cholesterol from 9 mmol/L before to 3 mmol/L after apheresis. At age 12 years, simvastatin was added to her treatment. Two years later, she underwent aortic valve replacement and coronary artery bypass grafting. Over the next few years she developed impaired exercise tolerance and was treated surgically at age 17 years with a combined heart and liver transplant, followed by long-term cyclosporine immunosuppression to prevent transplant organ rejection. Following the liver transplant her serum total cholesterol was well controlled at 5 mmol/L on low-dose atorvastatin.

At the age of 27 she gave birth to a healthy daughter, who has heterozygous FH.

Thirteen years after the combined heart and liver transplantation she developed symptomatic ischaemic heart disease and chronic liver disease due to autoimmune rejection. She therefore underwent a second liver transplantation and coronary artery stents were inserted. Following the second liver transplant her serum cholesterol remained in the target range without medication. At age 34 she had a myocardial infarction and cardiac arrest. After resuscitation a cardiac defibrillator was implanted. At age 40 she was experiencing recurrent angina and breathlessness. An echocardiogram showed moderate to severe aortic regurgitation without stenosis. A normal-sized left ventricle demonstrated mild impairment of global systolic function. There was a non-dilated right ventricle with mildly impaired global systolic function, moderately dilated left and right atria, and mild to moderate mitral and tricuspid regurgitation.

A year later she had a fatal cardiac arrest due to malfunction

of the implantable defibrillator. A diagnosis of underlying cardiac allograft vasculopathy was made on the basis of the echocardiographic findings and clinical details.

Her daughter with heterozygous FH has been responding well to treatment with pravastatin 10mg, which has reduced her LDL cholesterol from 5.0 to 3.5 mmol/L.

Genetic testing identified two mutations in the low-density lipoprotein receptor (LDL-R) gene; both mutations are known to disrupt LDL receptor function. One mutation in exon 4, c.633_683 dup (p.Asp221_Asp227), influences the ligand binding domain of the receptor.¹ The other mutation in exon 10, c.1444G>A (p.Asp482 Asn), influences the epidermal growth factor domain of the receptor and influences the intracellular release of LDL and receptor recycling. These bi-allelic mutations confirm a diagnosis of HoFH. Her daughter is heterozygous for the exon 10 mutation and has no evidence of the exon 4 mutation, consistent with a diagnosis of heterozygous FH.

Cultured skin fibroblasts incubated for 48 hours with labeled LDL to determine LDL binding to cells,² demonstrated that LDL receptor activity was less than 2% of normal. This is known as being LDL-R negative or as a null variant.

The pedigree causing this compound heterozygous FH condition is shown in figure 1. Total cholesterol levels in mmol/L are shown for family members. These suggest that the maternal exon 4 mutation (shown by light half-filled symbols) causes higher total cholesterol levels than the paternal exon 10 mutation (dark half-filled symbols). The index patient (arrow) has a clinical phenotype of HoFH.

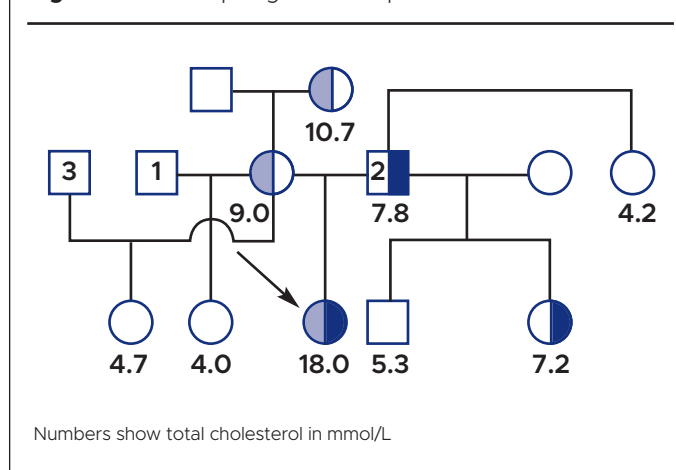
Using updated recommendations by the European Atherosclerosis Society on genetic terminology, these findings are consistent with the diagnosis of a monogenic, bi-allelic, semi-dominant, LDL-R loss of function-related, null-variant FH genotype and a homozygous FH phenotype.³

Discussion

HoFH is a rare condition which results in markedly elevated plasma low-density lipoprotein cholesterol (LDL-C) levels from birth and early-onset cardiovascular disease.³ Over the last decade there has been much progress in understanding the genetic complexity of this condition and in developing new treatments to prevent cardiovascular disease. Clinical criteria suggestive of a diagnosis of HoFH are an untreated LDL-C >10 mmol/L, xanthomas before the age of 10 years and/or untreated elevated LDL-C levels consistent with heterozygous FH in both parents. Other conditions associated with high LDL-C should be excluded, such as sitosterolaemia and lysosomal acid lipase deficiency. Updated genetic criteria for diagnosis of HoFH include confirmation of bi-allelic pathogenic or likely pathogenic variants on different chromosomes or two or more such variants at different loci.¹

Early treatment is recommended. Responses to statins, ezetimibe and proprotein convertase subtilisin/kexin type 9 (PCSK9) inhibitors depend on the degree of LDL-R activity.⁴ With some new drugs such as evinacumab, which works by inhibiting angiopoietin-like protein 3 (ANGPTL3) and thus increasing the activity of lipoprotein lipase and endothelial lipase, and with

Figure 1. Genetic pedigree of the patient



lipoprotein apheresis, response is independent of LDL-R function. Lomitapide is another useful novel therapy since it reduces VLDL production.

Lipoprotein apheresis is the foundation of treatment in addition to lipid-lowering drugs. There is strong evidence for its benefit, with resolution of clinical manifestations and no major safety concerns. Lipoprotein apheresis should be started preferably by the age of three years and should be performed every two weeks or even weekly.

Emerging therapies in development include gene transfer and gene editing.

Liver transplantation is an option for severely affected children with bi-allelic null variants. It is considered as a last resort if there has been a suboptimal response to cholesterol-lowering medication and apheresis.⁴ Liver transplantation corrects the molecular defects of LDL clearance. Since about 75% of LDL receptors are located in the liver, liver transplantation provides functional hepatic LDL receptors and normal LDL uptake into liver cells. Combined liver and heart transplantation may be indicated for rapidly progressive cardiovascular disease or extensive heart damage.⁵ Normal LDL-C levels are usually achieved within a few weeks after transplantation of a normal liver and may persist for up to 28 years.⁶ A systematic review of the literature on liver transplantation for HoFH concludes that it may improve prognosis and quality of life.⁶

Cardiac allograft vasculopathy (CAV) limits long-term survival after cardiac transplantation.⁷ It is a form of autoimmune coronary artery disease characterised by fibrous intimal hyperplasia in coronary vessels. CAV is caused by various factors including the immune response to the allograft, ischaemia reperfusion injury, viral infection, immunosuppressive drugs and classic risk factors such as hyperlipidaemia and hypertension.

Methods used for the diagnosis and assessment of CAV include intracoronary ultrasound, coronary angiography and intracoronary Doppler flow velocity measurement. Management of this condition involves the use of statins, angiotensin-



Key messages

- ▲ Homozygous familial hypercholesterolaemia is characterised by LDL-cholesterol > 10 mmol/L and xanthomas and cardiovascular disease presenting in childhood
- ▲ Lipid-lowering drugs are only moderately effective and lipoprotein apheresis is the mainstay of treatment
- ▲ Early diagnosis and early combination treatments are required to prevent rapid progression of cardiovascular disease
- ▲ If LDL receptor activity is absent, treatments that are independent of receptor activity are required

converting enzyme (ACE) inhibitors, new immunosuppressive drugs and the use of revascularisation procedures.

The patient described in this report meets the clinical criteria for the diagnosis of HoFH by having an initial extremely high untreated total cholesterol, xanthomas before the age of 10 years and with both her parents having total cholesterol levels consistent with heterozygous FH. She, in addition, meets the genetic criteria for a diagnosis of HoFH by having bi-allelic pathogenic mutations in the LDL receptor gene.³ As she had no LDL receptor activity, she did not respond well to probucol and simvastatin treatment and required biweekly apheresis to lower total cholesterol to 4 mmol/L. Despite treatment during childhood, atherosclerotic vascular disease became progressively worse and she required cardiac transplantation to restore cardiac function and liver transplantation to improve lipid management. Immune rejection of the transplanted organ, despite immunosuppressive medication, led to the need for a second liver transplant as well as the development of cardiac allograft immune vasculopathy. This immunologic vasculopathy, rather than atherosclerosis, led to the deterioration in cardiac function during adulthood and probably caused fatal coronary heart disease.

Conclusion

This report illustrates the challenges faced in managing HoFH without LDL receptor activity. Liver transplantation provided active LDL receptors and better lipid control. Cardiac transplant survival was determined by immune transplant organ rejection which causes cardiac allograft immunologic vasculopathy.



© 2024. This work is openly licensed via CC BY 4.0.

This license enables reusers to distribute, remix, adapt, and build upon the material in any medium or format, so long as attribution is given to the creator. The license allows for commercial use. CC BY includes the following elements: BY – credit must be given to the creator.

Copyright ownership The author(s) retain copyright.

Conflict of interest None to declare.

Funding None

Acknowledgments 1. The Medical Research Council Lipoprotein Team, Hammersmith Hospital, London for the initial family genetics study and LDL receptor activity bioassay; 2. The Northeast Thames regional genetics service at Great Ormond Street Hospital, London for genetic studies on the patient and her daughter to confirm the original findings.

References

1. Goldstein JL, Brown MS. Binding and degradation of low density lipoproteins by cultured human fibroblasts. *J Biol Chem* 1974; **249**(16): 5153–62. PMID:4368448
2. Bayley GR. Lipids and disorders of lipoprotein metabolism. The LDL receptor. *Clinical biochemistry: metabolic and clinical aspects* (3rd edition). Churchill Livingstone 2014, pp 702–36.
3. Cuchel M, Raal FJ, Hegele RA, *et al.* 2023 Update on European Atherosclerosis Society consensus statement on homozygous familial hypercholesterolaemia: new treatments and clinical guidance. *Eur Heart J* 2023;**44**(25): 2277–91. <https://doi.org/10.1093/eurheartj/ehad197>
4. France M, Rees A, Datta D, *et al.* HEART UK statement on the management of homozygous familial hypercholesterolaemia in the United Kingdom. *Atherosclerosis* 2016;**255**:128–39. <https://doi.org/10.1016/j.atherosclerosis.2016.10.017>
5. Mohamed F, Seedat F, Raal FJ. Novel therapies for familial hypercholesterolemia. *Curr Opin Endocrinol Diabetes Obes* 2021; **28**:188–95. <https://doi.org/10.1097/MED.0000000000000590>
6. Mlinaric M, Bratanic N, Dragos V, *et al.* Case report: liver transplantation in homozygous familial hypercholesterolemia, long term follow up of a patient and literature review. *Front Pediatr* 2020;**8**:567895. <https://doi.org/10.3389/fped.2020.567895>
7. Ramzy D, Rao V, Brahm J, *et al.* Cardiac allograft vasculopathy: a review. *Can J Surg* 2005;**48**(4):319–27. PMID:16149368