

# Diabetic retinopathy in newly diagnosed diabetes after kidney and liver transplantation

AISHA HAMID, SURJIT K GOLAR, HELEN M WHARTON, MARGARET CLARKE, ALEX WRIGHT

## Abstract

**New onset of diabetes is a well-recognised complication of whole organ transplantation. Screening for diabetes-related complications is recommended once diabetes is diagnosed, but little is known about the microvascular complications in this group of patients. Of the 57 patients who were screened within two years of kidney and liver transplantation, 53 had assessable images and these showed background changes in ten patients (19%) and background with maculopathy in two patients (3.7%). The prevalence of retinopathy was similar to that reported in newly diagnosed type 2 diabetes. One of 35 patients developed maculopathy on limited follow-up. Further follow-up beyond two years will be required to document the natural history of diabetic retinopathy in this group of patients.**

*Br J Diabetes* 2017;**17**:17-18

**Key words:** diabetic retinopathy, whole organ transplantation, post-transplant diabetes, screening.

## Introduction

Post-transplant diabetes (PTD) is a well-recognised complication of whole organ transplants, first noted in 1964,<sup>1</sup> and immunosuppressive therapies are likely to play a part in the development of diabetes. There is variation in reported rates of PTD due to differences in immunosuppressive regimens, diagnostic criteria and ethnicity. For example, rates of PTD vary from 2% to 53% after kidney transplantation, 40% after liver transplantation, 29% after heart and 42% after lung transplantation,<sup>2</sup> depending to some extent on the amount of preoperative screening as 8.1% of a pre-transplant population were found to have undiagnosed diabetes.<sup>3</sup> Higher rates have been found in some ethnic groups.<sup>4</sup> Some but not all studies suggest that new-onset diabetes after transplantation has an adverse effect on graft survival and may increase cardiovascular mor-

bidity and mortality, but little is known about the microvascular complications of this group of patients.<sup>5</sup> Screening for complications is recommended once diabetes has been diagnosed after transplantation.<sup>6</sup> Diabetes occurring after transplantation could provide a more precise date of onset of type 2 diabetes than is usually determined in ordinary clinical practice. Diabetic retinopathy may be found in 10–20% of patients with newly diagnosed type 2 diabetes,<sup>7,8</sup> and we surmised that the prevalence would be lower in new-onset diabetes after transplantation. This study aimed to assess retinopathy in a cohort of patients with PTD.

## Methods

Records of 552 organ transplantations (343 kidney and 209 liver) at the Queen Elizabeth Hospital Birmingham between 2007 and 2014 were examined for evidence of PTD. Drugs used for immunosuppression were prednisolone together with tacrolimus or mycophenolate. Patients with pre-existing diabetes, temporary post-transplant hyperglycaemia, and those living outside the Birmingham, Solihull and Black Country Diabetic Eye Screening Programme area were excluded. The timing and results of retinal screening, using digital photography with mydriasis, were analysed in all patients with PTD. The UK national diabetic retinopathy grades were used.

## Results

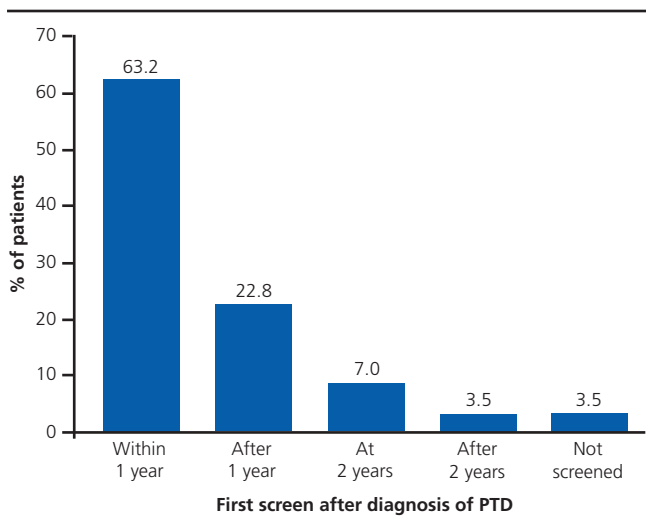
Diabetes was diagnosed in 49 patients (14.3%) after kidney transplants and eight patients (3.8%) after liver transplants. Mean age at screening was 56 years (range 19–80 years); 27 were male and 31 female. The reasons for kidney transplant were forms of nephritis (n= 12), IgA nephropathy (n= 8), hypertension (n=7), end-stage renal failure of uncertain cause (n=8), small kidney (n=6), neurogenic reflux (n=2), ischaemia (n=2), drugs (n=2), cystinosis (n=1) and polyarteritis (n=1). The reasons for liver transplant were forms of hepatitis A/B/C (n=5), alcohol (n=1) and liver failure of uncertain cause (n=2).

Retinal screening photographs were taken within two years of diagnosis of PTD in 53 (92.9%) patients (Figure 1). In those photographs that were assessable, no retinopathy was found in 40 patients (76.9%), 10 patients (19%) had background changes but no maculopathy (R1/M0) and two patients (3.7%) had background retinopathy with maculopathy (R1/M1). In one patient the photographs could not be assessed (Table 1). Maculopathy was confirmed by an ophthalmologist in two patients. No patient developed features of pre-proliferative or proliferative

Birmingham, Solihull and Black Country Diabetic Eye Screening Programme, Birmingham Heartlands Hospital, Birmingham, UK

**Address for correspondence:** Dr Aisha Hamid  
Diabetes & Endocrinology Centre, Birmingham Heartlands Hospital,  
Bordesley Green East, Birmingham, B9 5SS, UK  
Tel: +44 (0)121 424 2039  
E-mail: aisha.hamid@heartofengland.nhs.uk

<http://dx.doi.org/10.15277/bjd.2017.119>

**Figure 1.** Percentage of patients screened after diagnosis of post-transplant diabetes**Table 1** Number of patients with retinopathy grading outcome related to time of screening after diagnosis of post-transplant diabetes

Retinopathy grade	Within 1 year	After 1 year	After 2 years
R0M0	28	9	3
R1M0	5	3	2
R1M1	2	0	0
U	0	0	1

retinopathy and laser/anti-VEGF therapy was not required for maculopathy.

## Discussion

The prevalence of retinopathy will to some extent depend on access to healthcare, on whether the diagnosis of diabetes arose from screening or from the investigation of symptomatic patients, and on the prevalence of other risk factors for retinopathy such as hypertension. Currently in the UK, diabetic retinopathy has been reported in 19% of newly diagnosed patients with diabetes.<sup>8</sup> The rate of detection of referable diabetic retinopathy may also be affected by the promptness or otherwise of screening.<sup>9</sup>

PTD could provide evidence of the minimum rate of retinopathy to be expected at the diagnosis of type 2 diabetes, depending on the care of ascertainment of diabetes pre-transplant. In our study, diabetes was excluded before transplantation by random blood glucose measurements but not by systematic glucose tolerance testing. The diagnosis of PTD was delayed for at least six weeks after surgery. The prevalence of retinopathy in our group of patients was not different from reports in type 2 diabetes in general. Whether the retinopathy was due to diabetes, hypertension or other factors cannot be determined from this study. The incomplete follow-up



## Key messages

- Rates of diabetic retinopathy after organ transplantation are similar to those at diagnosis of type 2 diabetes
- All patients with post transplant diabetes should be offered diabetic eye screening within 3 months of diagnosis
- Longer follow up studies are required to assess the risk of developing sight threatening diabetic retinopathy in cohort of high risk patients

of this group of patients suggests that the natural history of the retinopathy is similar to other patients with type 2 diabetes.

Our results suggest that careful screening for diabetes with both blood glucose and HbA<sub>1c</sub> measurements should be undertaken before transplantation.

The study showed that screening was undertaken in only 60% of patients within one year of diagnosis, which did not meet the national screening guidelines which recommend that screening should be completed within three months of diagnosis. However, 93.0% of patients were screened within two years. Further efforts are required to improve the screening uptake, although it is appreciated that this group of patients have significant medical issues and retinal screening may get overlooked due to other priorities.

**Conflict of interest** Previously presented at BARS and EASDec conferences.

**Funding** None.

## References

1. Starzl TE, Marchioro TL, Rifkind D, *et al.* Factors in successful renal transplantation. *Surgery* 1964;**56**:296-318.
2. Sharif A, Cohn S. Post-transplant diabetes – state of the art. *Lancet Diabetes Endocrinol* 2016;**4**:337-49. [http://dx.doi.org/10.1016/S2213-8587\(15\)00387-3](http://dx.doi.org/10.1016/S2213-8587(15)00387-3)
3. Bergrem HA, Valderhaug TG, Hartmann A, *et al.* Undiagnosed diabetes in kidney transplant candidates: a case-finding strategy. *Clin J Am Soc Nephrol* 2010;**5**:616-22. <http://dx.doi.org/10.2215/CJN.07501009>
4. Montori VM, Basu A, Erwin PJ, Velosa JA, Gabriel SE, Kudva YC. Post-transplant diabetes: a systematic review of the literature. *Diabetes Care* 2002;**25**:583-92. <https://doi.org/10.2337/diacare.25.3.583>
5. Tufton N, Ahmed S, Rolfe C, Rajkariar R, Byrne C, Chowdhury TA. New-onset diabetes after renal transplantation. *Diabet Med* 2014;**31**:1284-92. <http://dx.doi.org/10.1111/dme.12534>
6. Wilkinson A, Davidson J, Dotta F, *et al.* Guidelines for the treatment and management of new-onset diabetes after transplantation. *Clin Transplant* 2005;**19**:291-8. <https://doi.org/10.1111/j.1399-0012.2005.00359.x>
7. Kostev K, Rathmann W. Diabetic retinopathy at diagnosis of type 2 diabetes in the UK: a database analysis. *Diabetologia* 2013;**56**:109-11. <http://dx.doi.org/10.1007/s00125-012-2742-7>
8. Looker HC, Nyangoma SO, Cromie D, *et al.* Diabetic retinopathy at diagnosis of type 2 diabetes in Scotland. *Diabetologia* 2012;**55**:2335-42. <http://dx.doi.org/10.1007/s00125-012-2596-z>
9. Scanlon PH, Aldington SJ, Stratton IM. Delay in diabetic retinopathy screening increases the rate of detection of referable diabetic retinopathy. *Diabet Med* 2014;**31**:439-42. <http://dx.doi.org/10.1111/dme.12313>