

Hepatic abscess secondary to a duodenal-jejunal bypass liner successfully treated with antibiotics without removal of the device

ROBERT EJ RYDER,¹ RUSSELL DRUMMOND,² PIYA SEN GUPTA³

Br J Diabetes 2024;**24**(1):99-102
<https://doi.org/10.15277/bjd.2024.445>

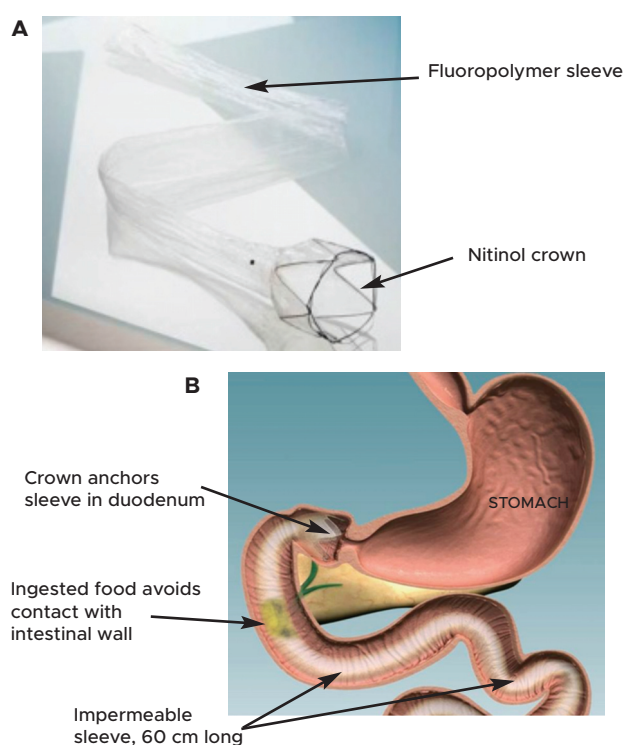
Key words: hepatic abscess, liver abscess, antibiotics, case report, duodenal-jejunal bypass liner, DJBL, EndoBarrier, RESET, diabetes, obesity, weight loss

Introduction

With rising incidence of obesity and co-existent type 2 diabetes (T2DM),¹ there is an imperative to determine effective and safe strategies to treat both conditions simultaneously. Based on the evidence identified for their guideline, the National Institute for Health and Care Excellence (NICE) lists the conditions that can improve after bariatric surgery as including cardiovascular disease, hypertension, idiopathic intracranial hypertension, non-alcoholic fatty liver disease with or without steatohepatitis, obstructive sleep apnoea and T2DM.² NICE goes on to recommend that an expedited assessment for bariatric/metabolic surgery be offered to those with a body mass index (BMI) 35 kg/m² or over (or lower in certain ethnicities such as the South Asian population) with a diagnosis of T2DM within the last 10 years who are also receiving, or will receive, assessment in a specialist weight management service.²

Studies of bariatric/metabolic surgery combined with intensive medical therapy compared to intensive medical therapy alone have demonstrated superior outcomes in glycaemic control, weight reduction and quality of life among other measures, even up to 10 years later.³ However, in reality surgery is performed worldwide in only a small proportion (0.1-2%) of those who would be eligible.⁴ The reasons for this may be due to surgical capacity constraints and patient choice,⁵ given irreversible changes to the anatomy, potentially serious adverse outcomes including anastomotic leak and stricture,³ cholelithiasis, nutritional deficiencies requiring lifelong supplementation, requirement for long follow-up after the

Figure 1. The Endobarrier device (A) and a diagram of the device in situ (B)



Adapted from http://www.diabetologists-abcd.org.uk/Research/What_Endobarrier.htm.

surgery, cosmetic concerns and adverse psychological effects.

The duodenal-jejunal bypass liner (DJBL), also known as EndoBarrier® or RESET®, is a device (Figure 1) placed endoscopically for up to one year which mimics the proximal intestinal bypass effect of a Roux-en-Y gastric bypass (RYGB) procedure. It is placed by trained endoscopists as a day case and promoted significant weight loss of 18.9% and improvement in glycaemic control (haemoglobin A1c [HbA_{1c}] reduction of 13.3 mmol/mol [1.3%]) in a meta-analysis comprising 388 patients from 14 studies⁶, with lasting effects three years after device removal.⁷ Furthermore, it may be considered in those patients who are deemed too high risk to undergo conventional, more invasive, bariatric surgery. It has the advantage of being removable, should complications arise. In the US, a randomised

¹ City Hospital, Sandwell and West Birmingham Hospitals NHS Trust, Birmingham, UK

² North Glasgow Diabetes, Endocrinology and Clinical Pharmacology, Glasgow

³ Department of Diabetes, Guy's and St Thomas' Hospital, London

Address for correspondence: Dr Robert EJ Ryder
 City Hospital, Sandwell and West Birmingham Hospitals NHS Trust,
 Dudley Road, Birmingham, B18 7QH, UK
 Email: bob.ryder@nhs.net

controlled trial was undertaken comparing DJBL (216 patients) to a sham procedure with moderate-intensity lifestyle intervention (109 patients).⁸ The study achieved good clinical outcomes, with an 8.7 mmol/mol (0.8%) greater fall in HbA_{1c} in the DJBL group compared to the sham procedure group alongside greater weight loss and better cardiometabolic outcomes.⁸ However, hepatic abscess occurred in seven cases (3.2%), and this led to the trial being stopped prematurely by the sponsoring company (GI Dynamics, Boston USA), notwithstanding the good clinical outcomes in these hepatic abscess patients.⁸ Subsequent studies suggest an incidence of hepatic abscess closer to 1% around the world,⁹ compared to the 3.2% rate found in the US study. Other serious adverse events in studies to date include gastrointestinal bleeding, device migration, device obstruction and abdominal discomfort.¹⁰ Abscess formation is thought to be due to the device itself acting as a nidus of infection,¹⁰ often necessitating removal of the device.

In this case report we demonstrate that hepatic abscess in patients with DJBL may be treated without the need for device removal or invasive percutaneous abscess drainage, with intravenous antibiotics alone, in selected cases.

Patient information

The patient was a 51-year-old female with T2DM. Her weight was 136.2 kg (BMI 53.9 kg/m²). She was receiving gliclazide 160 mg twice daily and liraglutide 1.8 mg daily. Her HbA_{1c} was 73 mmol/mol (8.8%). She was a participant in the ABCD REVISE Diabetesity (ISRCTN00151053) trial.¹¹

This patient presented six weeks following DJBL insertion in July 2014 with nausea, upper abdominal pain and fever; her C-reactive protein (CRP) was 232 mg/L (reference range 0 – 10), her white blood cell count (WCC) was normal. She was found to have an 8.0 x 6.5 cm abscess in the left hepatic lobe on CT imaging (Figure 2). It was not amenable to ultrasound-guided drainage as blood vessels running anterior to the liver made the abscess difficult to access.

She was treated with intravenous antibiotics and strongly advised to have the device removed. After consideration, she declined due to her successful weight loss and anticipated further weight loss. Therefore she was treated with antibiotics, with an agreement that if there was no resolution of the abscess then the device would be removed prematurely (before 12 months).

She was treated with two weeks of intravenous piperacillin/tazobactam followed by 12 weeks of oral ciprofloxacin, resulting in clinical and radiological improvements with a reduced abscess size on interval CT to 2.5 x 2.0 cm. There was only a small abscess remnant to be seen following device removal at 12 months (Figure 3). Her CRP fell to 34 mg/L and her WCC remained normal. During that time, her weight fell by 18.9 kg to 117.3 kg prior to device removal, though her HbA_{1c} rose to 82.5 mmol/mol (9.7%) (with gliclazide halved and liraglutide stopped). Her progress during her year of treatment is summarised and illustrated in Figure 4. Immediately following device removal her weight was 116.2 kg (20 kg less than

Figure 2. Computer tomography (CT) scan of abdomen undertaken six weeks following duodenal-jejunal bypass liner (DJBL) insertion

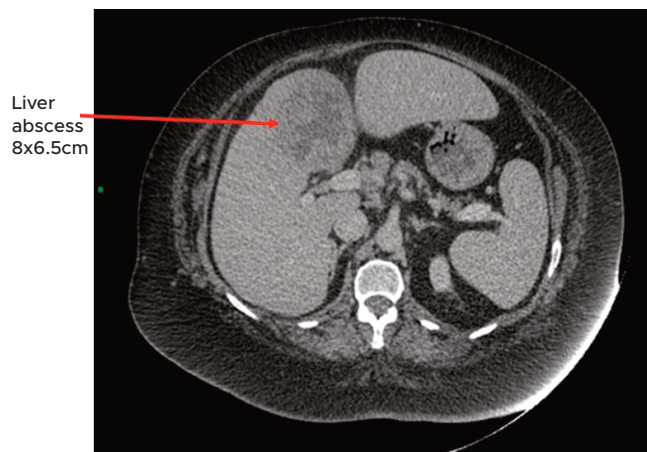
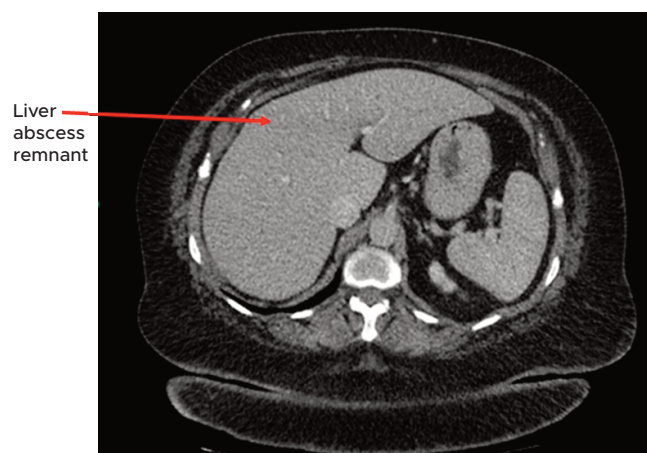


Figure 3. Computer tomography (CT) scan of abdomen undertaken following DJBL removal at 12 months

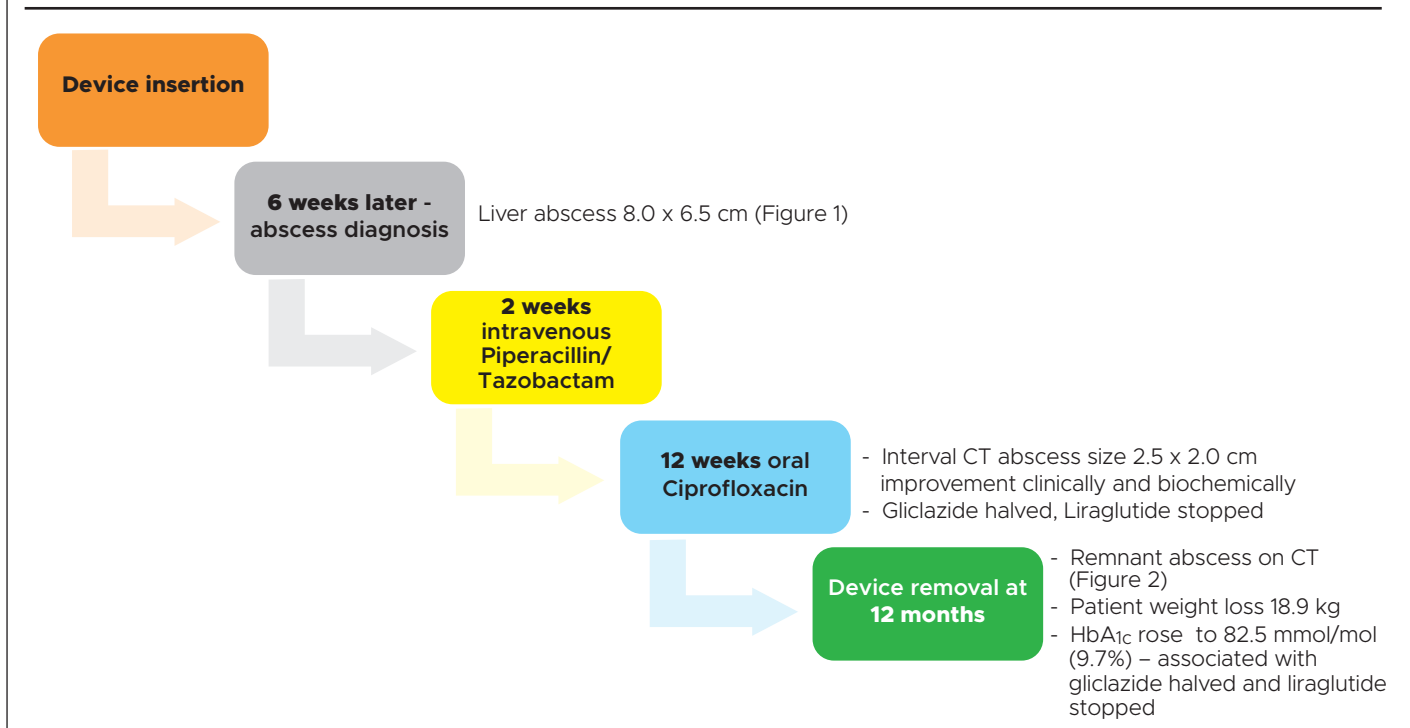


baseline) and one year later her weight was 118.8 kg (17.4 kg less than baseline), showing that she had maintained the improvement sustained from the year with DJBL, as occurs in the majority of DJBL-treated patients.^{12,13}

Discussion

Most studies of DJBL use are limited by small sample size. In previous cases of hepatic abscess, intervention mostly taken the form of device removal followed by intravenous antibiotics, either alone or alongside drainage of the abscess.¹⁰ As overall cases of hepatic abscess remain low, the evidence from these small trials is important in the development of guidance for treating this rare but potentially life-threatening condition in the safest and most effective manner. The risks of adverse outcomes and their treatments also must be balanced against the improvements in patient outcomes from the treatment itself.

Figure 4. Progress during a year of treatment with DJBL complicated by liver abscess at six weeks




Key messages

- ▲ Duodenal-jejunal bypass liner (DJBL), also known as EndoBarrier® or RESET®, is an effective endoscopic treatment for refractory diabetes, and is less invasive than bariatric surgery.
- ▲ Hepatic abscess is a rare complication of DJBL treatment which is usually treated with removal of DJBL and percutaneous abscess drainage.
- In the case reported here, the abscess was successfully treated with antibiotics without removal of DJBL or percutaneous abscess drainage, and this allowed the patient to lose a considerable amount of weight, which weight loss she maintained during the year after removal.
- This case study shows that conservative management of hepatic abscess secondary to DJBL can be considered, rather than device removal, so long as affected patients are closely followed up.

Our patient had a positive outcome from her inclusion in the trial in the form of significant weight loss, which she was able to maintain after device removal. This is in keeping with our experience that about 80% of patients are able to maintain their improvement one year after DJBL removal,^{12,13} with 77%

maintaining the improvement three years after removal.⁷ This patient also had reduced medication burden, and the safety and efficacy of conservative management of hepatic abscess in this context have been demonstrated. Device removal is more likely to be undertaken due to other adverse events, particularly abdominal pain.¹⁴ It is noted that the HbA_{1c} might not have deteriorated if diabetes medications had not been discontinued (including liraglutide 1.8 mg daily), as is notably happening in the UK with current glucagon-like peptide-1 receptor antagonist (GLP-1 RA) shortages.¹⁵ This case presents an argument for not discontinuing GLP-1 RAs automatically in those treated with this device in future if clinically indicated. Some clinicians would consider stopping GLP-1 RA in those with abdominal pain and utilising alternatives such as insulin if diabetes control is declining.

This case study shows that conservative management of hepatic abscess secondary to this device can be considered, rather than device removal, so long as affected patients are closely followed up. However, further case studies are required to consolidate findings from this case report.

 © 2024. This work is openly licensed via CC BY 4.0. This license enables reusers to distribute, remix, adapt, and build upon the material in any medium or format, so long as attribution is given to the creator. The license allows for commercial use. CC BY includes the following elements: BY – credit must be given to the creator.

Conflict of interest REJR has received speaker fees, and/or consultancy fees and/or educational sponsorships from Abbott, Besins, BioQuest, Morphic Medical and Novo Nordisk.

PSG has received speakers fees from Novo Nordisk.

Funding None.

References

1. International Diabetes Federation. IDF diabetes atlas, 10th ed. 2021. <https://www.diabetesatlas.org/> (accessed 09 January 2024).
2. Nice.org.uk. 2023. 1 Recommendations | Obesity: identification, assessment and management | Guidance | NICE. [online] Available at: <https://www.nice.org.uk/guidance/cg189/chapter/1-Recommendations#bariatric-surgery-for-people-with-recent-onset-type-2-diabetes> (accessed 09 January 2024).
3. Mingrone G, Panunzi S, De Gaetano A, *et al*. Metabolic surgery versus conventional medical therapy in patients with type 2 diabetes: 10-year follow-up of an open-label, single-centre, randomised controlled trial. *Lancet* 2021;**397**(10271):293-304. [https://doi.org/10.1016/S0140-6736\(20\)32649-0](https://doi.org/10.1016/S0140-6736(20)32649-0)
4. Dixon JB. Regional differences in the coverage and uptake of bariatric-metabolic surgery: a focus on type 2 diabetes. *Surg Obes Relat Dis* 2016;**12**:1171-7. <https://doi.org/10.1016/j.soard.2015.11.027>
5. Fung M, Wharton S, Macpherson A, Kuk JL. Receptivity to bariatric surgery in qualified patients. *J Obes* 2016;**2016**:5372190. Epub 2016 Jul 19. <https://doi.org/10.1155/2016/5372190>
6. Jirapinyo P, Haas AV, Thompson CC. Effect of the duodenal-jejunal bypass liner on glycemic control in patients with type 2 diabetes with obesity: a meta-analysis with secondary analysis on weight loss and hormonal changes. *Diabetes Care* 2018;**41**(5):1106-15. <https://doi.org/10.2337/dc17-1985>
7. Ryder REJ, Yadagiri M, Burbridge W, *et al*. Duodenal-jejunal bypass liner for treatment of T2DM and obesity: 4-year outcomes in the first National Health Service (NHS) EndoBarrier service. *Br J Diabetes* 2022;**22**:82-6. <https://doi.org/10.15277/bjd.2022.351>
8. Thompson CC, Jirapinyo P, Brethauer S, *et al*. A multicenter randomized sham-controlled trial of a duodenal jejunal bypass liner for the treatment of type 2 diabetes mellitus. *Gastrointestinal Endoscopy* 2022;**95**(Suppl):AB10-AB11. <https://doi.org/10.1016/j.gie.2022.04.076>
9. Ryder REJ, Laubner K, Benes M, *et al*. Endoscopic duodenal-jejunal bypass liner treatment for type 2 diabetes and obesity: glycemic and cardiovascular disease risk factor improvements in 1,022 patients treated worldwide. *Diabetes Care* 2023;**46**:e89-e91. <https://doi.org/10.2337/dc22-1952>
10. Ruban A, Ashrafian H, Teare JP. The EndoBarrier: duodenal-jejunal bypass liner for diabetes and weight loss. *Gastroenterology Research Practice* 2018; 2018: Article ID 7823182. <https://doi.org/10.1155/2018/7823182>
11. Randomisation to Endobarrier alone Versus with Incretin analogue in SustainEd Diabetes (REVISE-Diabetes). <https://classic.clinicaltrials.gov/ct2/show/NCT02055014> (accessed 20 Feb 2024)
12. Ryder REJ, Yadagiri M, Burbridge W, *et al*. The United Kingdom's first NHS EndoBarrier service for long-standing poorly controlled type 2 diabetes and obesity: outcomes one year after EndoBarrier removal. *Br J Diabetes* 2021;**21**:76-83.
13. Ryder REJ, Yadagiri M, Burbridge W, *et al*. EndoBarrier treatment for longstanding type 2 diabetes and obesity: outcomes one year after EndoBarrier in 90 consecutively treated patients. *Practical Diabetes* 2022;**39**(3):13-16a. <https://doi.org/10.1002/pdi.2393>
14. Caiazzo R, Branche J, Raverdy V, *et al*. Efficacy and safety of the duodeno-jejunal bypass liner in patients with metabolic syndrome. *Annals Surgery* 2020;**272**(5):696-702. <https://doi.org/10.1097/SLA.0000000000004339>
15. <https://www.cas.mhra.gov.uk/ViewandAcknowledgment/ViewAlert.aspx?AlertID=103235> (accessed 16 Jan 2024)



Association of
**British Clinical
Diabetologists**

ABCD Nationwide Closed-Loop Audit re-launching Soon!

Following the success of the ABCD NHS England Closed-Loop pilot, we are about to re-launch a nationwide audit of **Hybrid Closed-Loop** in the UK to capture further data from the wide Closed-Loop data

**REGISTER YOUR CENTRE!
FOLLOW THE QR CODE!**



- you are invited to enter your patients' data into the **bespoke online tool**
- you will be able to **analyse your local data easily**
- the data will be automatically added to the **national data in anonymised form**
- we can provide **easy-to-complete paper proformas** for use in clinic if preferred