

Pembrolizumab and diabetes: a case of diabetic ketoacidosis in a patient with metastatic melanoma

SONGO J LOLOMARI,¹ SHEENA THAYYIL,² MARIE-FRANCE KONG³

Key words: pembrolizumab, type 1 diabetes mellitus, diabetic ketoacidosis, malignant melanoma, checkpoint inhibitor, immunotherapy

Introduction

The advent of immunotherapy has revolutionised the management of certain malignancies, and its use has increased over the past decade. Monoclonal antibody therapies known as checkpoint inhibitors work by enhancing the immune response against malignant cells by blocking the pathways that inhibit T-cell regulation. Checkpoint inhibitors can be administered alone or in combination as an intravenous infusion every 3-6 weeks for a maximum of two years. However, about 10% of patients may experience endocrine adverse effects. Thyroid disease and hypophysitis are those most commonly encountered; there are also reports of diabetes mellitus and primary adrenal insufficiency as well as rarer endocrinopathies.

Pembrolizumab, an immune checkpoint inhibitor, received FDA approval in 2014 for advanced melanoma, and in 2015 for metastatic non-small cell lung cancer. It is also approved for recurrent/metastatic head and neck cancer, and for refractory classical Hodgkin's lymphoma.

We report the case of a 75-year-old man who developed new-onset diabetes mellitus and diabetic ketoacidosis while undergoing pembrolizumab chemotherapy for metastatic melanoma. He was not taking steroids.

Case report

A 75-year-old retired construction worker and ex-smoker with a background of hypertension and COVID pneumonitis (August 2021) initially presented with a PT4b (>4 mm thickness and

ulcerated) malignant mole on his back, which was excised in July 2021. He was diagnosed with malignant melanoma (BRAF mutation negative). A PET scan in October 2021 showed metastatic disease. After discussion with the oncologist, the patient opted for palliative immunotherapy with pembrolizumab. Treatment was commenced in January 2022. After his first cycle, he complained of joint aches and itching which resolved shortly thereafter. After his second cycle, he reported chest tightness and decreased exercise tolerance and was diagnosed with asthma by his GP. He had a chest X-ray, which showed no obvious pneumonitis. In April 2022, three weeks after his third cycle of pembrolizumab and approximately 10 weeks after he started pembrolizumab, he reported nausea, polyuria and polydipsia when he attended his oncology follow-up appointment and had unintentionally lost approximately 2 stone in weight. His capillary blood glucose was 26 mmol/L. He was admitted to the oncology assessment unit and found to be in diabetic ketoacidosis (DKA) (pH 7.2 on venous blood gas and blood ketones 4 mmol/L). Sodium was 132 mmol/L, potassium 6.6 mmol/L, urea 10.8 mmol/L, creatinine 118 μ mol/L, eGFR 51, haemoglobin 139 g/L, white cell count 15.0×10^9 /L, platelets 601×10^9 /L and CRP 5 mg/L. He was transferred to the acute medical unit and treated for DKA according to the Trust protocol. He made an uneventful recovery.

There was no family history of autoimmune disease. Further investigations showed an HbA_{1c} of 9.3% (78 mmol/mol) and he was positive for anti-GAD antibody (>2,000 IU/mL) but negative for islet cell and anti-IA2 and anti-ZNT8 antibodies. Thyroid function tests and cortisol levels were normal. His glycaemic control was optimised on Levemir (8 units BD) and Novorapid (as required) before discharge home. The oncologist deferred his next cycle by a few weeks and, after discussion with the patient, pembrolizumab treatment was continued since endocrinopathies are not a contraindication to continuing treatment.

In June 2022, he developed polymyalgia rheumatica which was considered to be secondary to pembrolizumab. He was treated with steroids which led to an increase in his insulin requirement (Levemir 15 units in the morning and 9 units in the evening). His glycaemic control gradually improved and his HbA_{1c} in early December 2022 was 38 mmol/mol (5.6%). Unfortunately, although the metastatic melanoma initially responded well to pembrolizumab (as evidenced by shrinkage of the large right, upper lobe mass lesion shown on CT in May 2022) repeat CT scan in October 2022 showed an increase in

¹ Internal Medicine Trainee, University Hospitals of Leicester NHS Trust, Leicester, UK

² Diabetes and Endocrinology SpR, University Hospitals of Leicester NHS Trust, Leicester, UK

³ Consultant Physician, Diabetes & Endocrinology, University Hospitals of Leicester NHS Trust, Leicester, UK

Address for correspondence: Dr Marie-France Kong

Consultant Physician, Diabetes & Endocrinology, Department of Diabetes, Leicester General Hospital, University Hospitals of Leicester NHS Trust, Leicester, UK
E-mail: marie-france.kong@uhl-tr.nhs.uk

Br J Diabetes 2023;**23**:45-47
<https://doi.org/10.15277/bjd.2023.410>

the size of the large lung mass and also development of new satellite lesions. Pembrolizumab was therefore stopped due to the poor response to treatment. In February 2023 he was found to have new brain metastases. Sadly, he passed away in March 2023.

Discussion

Pembrolizumab is a checkpoint inhibitor antibody that enhances the T-cell-mediated immune response against malignant cells.¹ Its mechanism of action involves binding to the programmed death-1 (PD-1) protein on T-cell lymphocytes to prevent interaction with programmed death receptor ligand-1 (PD-L1) which is typically found in cancer cells and antigen-presenting cells (Figure 1).

The interaction between ligand and receptor leads to inhibition of T-cell function (Figure 1) and is a pathway designed to protect against autoimmunity hence acting as a 'checkpoint'.² By blocking this interaction, pembrolizumab promotes T-cell-mediated killing.

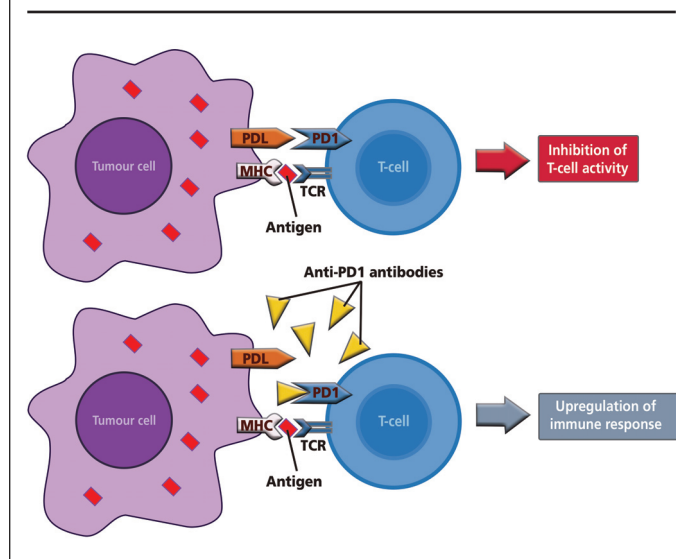
Based on data collected from clinical trials, pembrolizumab has been found to cause various immune-related adverse events such as pneumonitis, colitis, hepatitis, hypophysitis, hyperthyroidism, hypothyroidism, and nephritis.³ Only 0.1% of patients in clinical trials developed type 1 diabetes (T1DM) as an adverse event.

According to a systematic review by de Filette *et al*, only 0.4% of patients experience pembrolizumab-induced diabetes.⁴ The reported symptoms are consistent with those of classical diabetes, including dehydration, fatigue, excessive thirst, frequent urination and weight loss.⁴ The onset of diabetes can vary, with some cases being reported within four weeks of initiating therapy with immune checkpoint inhibitors while others have occurred after more than 12 months of receiving anti-PD-1 immunotherapy.^{5,6} Our patient reported symptoms 10 weeks after starting pembrolizumab. His last measured HbA_{1c} before he presented with DKA was done 31 months prior to the commencement of pembrolizumab and was normal at 28 mmol/mol (compared to 78 mmol/mol at the time of his DKA presentation). Since there were no HbA_{1c} results shortly before starting pembrolizumab, it is impossible to confirm the rate of development of hyperglycaemia. We would therefore recommend considering measurement of HbA_{1c} and blood glucose prior to the commencement of checkpoint inhibitors.

The exact mechanism of checkpoint inhibitor-induced T1DM is unclear. In mouse models, research found that blocking the PD-1/PD-L1 pathway led to the development of diabetes in female non-obese diabetic (NOD) mice with prediabetic conditions.⁷ A study in Japan also demonstrated a noticeable decrease in PD-1 expression in CD4+ T cells in patients with T1DM compared to healthy subjects.⁸ The current hypothesis is that PD-1 inhibitors cause T1DM by activation of autoreactive CD8+ T-cells that have the ability both to survive and to destroy β -cells.⁹

Recent reports suggest that the use of PD-1 and PD-L1 agents may lead to a 1% chance of diabetes mellitus (DM) occurrence, including new-onset T1DM or worsening of type 2

Figure 1. Diagram showing the PD-1 pathway and how PD-1 inhibitors such as pembrolizumab promote immune-mediated destruction of cancer cells¹⁴



DM (T2DM).^{4,10} In patients who develop T1DM, the mechanism appears similar to the permanent autoimmune process of T1DM, but with faster, aggressive destruction of beta islet cells, likely mediated by T-cells, requiring insulin replacement.^{10,11} Based on the presence of anti-GAD antibodies and the sudden onset of symptoms, we conclude that our patient developed T1DM after starting pembrolizumab.

DKA was found to be the most common first presentation in checkpoint inhibitor-induced T1DM (86% of patients).⁵ Other presentations include severe hyperglycaemia and ketonuria.⁵ Approximately 70% of patients who develop T1DM secondary to immunotherapy exhibit a recognised genetic predisposition to DM.¹² Positive autoantibodies were reported in about half of the patients, with reported cases of both pre-existing and newly developed autoantibodies.^{4,12} Anti-GAD was the most commonly reported autoantibody but others such as anti-IA-2, anti-ZnT8 and islet cell antibodies were also reported in patients with checkpoint inhibitor-induced diabetes.¹² This suggests that it might be worth considering checking diabetes autoantibodies prior to commencing checkpoint inhibitors. This might help to risk-stratify patients and guide which patients would benefit from closer glucose monitoring. The alternative cause of corticosteroid use should also be considered as a more common cause of hyperglycaemia. Our patient was not on any steroids at the time of developing diabetes.

Insulin therapy is typically necessary due to the aggressive pathophysiology of the disease. Unlike other immune-related adverse events, the use of glucocorticoids can worsen the disease process by increasing insulin resistance. There is no evidence to suggest that glucocorticoids can reverse beta cell damage. Immunotherapy is typically postponed until hyperglycaemia is under control, but it is not always necessary to discontinue treatment.¹³



Key messages

- New-onset diabetes mellitus (and potentially DKA, which can be life-threatening) is a rare adverse event of pembrolizumab therapy
- Patient and clinician education and awareness of this potential adverse event are vital

Conclusion

It is important to inform patients of the possibility of developing new-onset diabetes mellitus and potential DKA as a side effect when undergoing checkpoint inhibitor immunotherapy, even though it is rare. At present, there are no risk factors or dose-dependent toxicity that are known to precipitate autoimmune diabetes in patients taking pembrolizumab. As far as we know, there is a lack of established guidelines for clinicians to follow when monitoring patients who are starting pembrolizumab therapy. This is a crucial matter that requires further attention. To detect new-onset diabetes early and prevent DKA, patients should be advised about the symptoms to watch for. Consider lowering the threshold for glucose monitoring and advise patients to seek medical advice if they develop any concerning symptoms.

Conflict of interest None to declare.

Funding None.

This case report was presented at ABCD Diabetes Update 2023 on 2nd February, 2023 in Loughborough UK.

References

1. Mahoney K, Freeman G, McDermott D. The next immune-checkpoint inhibitors: PD-1/PD-L1 blockade in melanoma. *Clin Ther* 2015;**37**(4):764–82. <https://doi.org/10.1016/j.clinthera.2015.02.018>
2. Francisco L, Sage P, Sharpe A. The PD-1 pathway in tolerance and autoimmunity. *Immunol Reviews* 2010;**236**(1):219–42. <https://doi.org/10.1111/j.1600-065X.2010.00923.x>
3. Abdel-Wahab N, Shah M, Suarez-Almazor ME. Adverse events associated with immune checkpoint blockade in patients with cancer: a systematic review of case reports. *PLoS One* 2016;**11**(7):e0160221. <https://doi.org/10.1371/journal.pone.0160221>
4. de Filette J, Andreescu CE, Cools F, Bravenboer B, Velkeniers B. A systematic review and meta-analysis of endocrine-related adverse events associated with immune checkpoint inhibitors. *Horm Metab Res* 2019;**51**:145–56. <https://doi.org/10.1055/a-0843-3366>
5. Hughes J, Vudattu N, Sznol M, et al. Precipitation of autoimmune diabetes with anti-PD-1 immunotherapy. *Diabetes Care* 2015;**38**:e55–e57. <https://doi.org/10.2337/dc14-2349>
6. Okamoto M, Okamoto M, Gotoh K, et al. Fulminant type 1 diabetes mellitus with anti-programmed cell death-1 therapy. *J Diabetes Investig* 2016;**7**:915–18. <https://doi.org/10.1111/jdi.12531>
7. Fife B, Guleria I, Bupp M, et al. The programmed death-1 (PD-1) pathway regulates peripheral T cell tolerance during autoimmune diabetes in nonobese diabetic (NOD) mice. *Clinical Immunology* 2007;**123**:S27. <https://doi.org/10.1016/j.clim.2007.03.248>
8. Fujisawa R, Haseda F, Tsutsumi C, et al. Low programmed cell death-1 (PD-1) expression in peripheral CD4+T cells in Japanese patients with autoimmune type 1 diabetes. *Clinical Experimental Immunol* 2015;**180**(3):452–7. <https://doi.org/10.1111/cei.12603>
9. Hao J, Renno A, Imam S, Alfonso-Jaume M, Elnagar N, Jaume J. Development of type 1 diabetes after cancer immunotherapy. *AACE Clinical Case Reports* 2017;**3**(3):e242–e245. <https://doi.org/10.4158/EP161410.CR>
10. Quandt Z, Young A, Anderson M. Immune checkpoint inhibitor diabetes mellitus: a novel form of autoimmune diabetes. *Clin Exp Immunol* 2020;**200**:131–40. <https://doi.org/10.1111/cei.13424>
11. Kotwal A, Haddox C, Block M, Kudva YC. Immune checkpoint inhibitors: an emerging cause of insulin-dependent diabetes. *BMJ Open Diabetes Res Care* 2019;**7**:e000591. <https://doi.org/10.1136/bmjdr-2018-000591>
12. Stamatouli AM, Quandt Z, Perdigoto AL, et al. Collateral damage: insulin-dependent diabetes induced with checkpoint inhibitors. *Diabetes* 2018;**67**:1471–80. <https://doi.org/10.2337/dbi18-0002>
13. Haanen JBAG, Carbone F, Robert C, et al. Management of toxicities from immunotherapy: ESMO Clinical Practice Guidelines for diagnosis, treatment and follow-up. *Ann Oncol* 2018;**29**(Suppl 4):iv264–6. <https://doi.org/10.1093/annonc/mdx225>
14. Angelousi A, Chatzellis E, Kaltsas G. New Molecular, Biological, and Immunological Agents Inducing Hypophysitis. *Neuroendocrinology* 2017;**106**(1):89–100